

# Transrectal ultrasound guided biopsy: effect on natural history of multi-parametric MRI signal and derived quantitative parameters

Arash Latifoltojar<sup>1</sup>, Nikos Dikaos<sup>2</sup>, Ashley Ridout<sup>3</sup>, Caroline Moore<sup>4</sup>, Rowland Illing<sup>5</sup>, Alex Kirkham<sup>6</sup>, Clare Allen<sup>5</sup>, Stuart Taylor<sup>2</sup>, Steve Halligan<sup>2</sup>, David Atkinson<sup>2</sup>, Mark Emberton<sup>3</sup>, and Shonit Punwani<sup>2</sup>

<sup>1</sup>Centre for Medical Imaging, University College London, London, London, United Kingdom, <sup>2</sup>Centre for Medical Imaging, University College London, London, United Kingdom, <sup>3</sup>Urology, University College London Hospital, London, United Kingdom, <sup>4</sup>Urology, University College London, London, United Kingdom, <sup>5</sup>Radiology, University College London Hospital, London, United Kingdom, <sup>6</sup>Radiology, university College London Hospital, London, United Kingdom

**Target audience:** Radiologist and urologist with interest in multi-parametric prostate MRI

**Background:** Routine clinical practice on suspicion of prostate cancer is to perform transrectal ultrasound (TRUS) guided biopsy followed by pelvic MRI (T1 and T2-weighted) for staging of histologically confirmed prostatic tumour. Yet, the biopsy procedure itself hinders the diagnostic accuracy of MRI as post-biopsy haemorrhage within the prostate can mask/mimic the signal changes associated with tumour [1]. Previous studies suggest delaying MRI from 3 to up to 8 weeks [2,3] and also that the resolution of changes is not predictable for an individual [1]. Multi-parametric MRI (mp-MRI) is becoming increasingly important in the management pathway of patients with prostate cancer [4]. However, there is little published on the effect of TRUS biopsy on mp-MRI signal and derived quantitative parameters. This study documents the temporal evolution of prostate mp-MRI signal and derived quantitative parameters in patients following TRUS biopsy.

## Material and Methods:

**Patient cohorts:** 14 patients (aged 43-69, mean 64 years) with (i) elevated PSA (range 2.2-11.7, mean 6.2) and (ii) negative pre-biopsy mp-MRI report (Pi-RADS 1-2/5) underwent 10 core TRUS biopsy. As part of study, these patients had additional mp-MRI at one, two and six month post-biopsy. As a control group, a second cohort of 10 patients (aged 47-72 years, mean 62.6) with (i) elevated PSA (range 2.99-8, mean 5.5); (ii) biopsy performed a minimum of 12 month prior to MRI; (iii) a follow up MRI performed at least 12 month after the first MRI and (iv) negative MRI report for prostate cancer were selected from a database of patients undergoing mp-MRI active surveillance for low volume (<0.2 cc) and low grade (<=Gleason 3+4) disease. The mean time difference between the first and follow up scan in cohort group was 21.2 month (range 12-33 month).

**Mp-MRI protocol:** Both patient cohorts were scanned on 1.5T scanner. Axial pre-contrast multiple flip angle volume interpolated gradient echo T1-weighted (TE/TR=2.5/5.61ms, Slice thickness=3mm, matrix=192\*192, field of view=258mm), turbo spin echo (TSE) T2-weighted (TE/TR=92/5170, slice thickness=3mm, matrix=256\*256, field of view=180mm), diffusion weighted imaging (DWI) short tau inversion recovery (STIR) echo planar imaging (EPI) at b0, 150, 500 and 1000 s/mm<sup>2</sup> (TE/TR=96/2100, slice thickness=5mm, matrix=172\*172, field of view= 340mm) and dynamic contrast enhanced (DCE) images (TE=2.5ms, TR=5.61ms, slice thickness=3mm, matrix=192\*192, field of view=258mm, temporal resolution=17s) were acquired.

**Image analysis:** For analysis the prostate was divided into four zones, left and right peripheral zones and left and right transition zones. A volumetric region of interest (ROI) was placed in each region to cover the whole prostate gland. T2 signal intensity was normalized (nT2 SI) to the signal intensity from obturator internus muscle. T1 relaxation time (T<sub>10</sub>) values were derived from ROIs on pre-contrast 5°, 10°, 20° and 25° flip angle T1-weighted images. ADC values derived from ADC maps images generated by the scanner console from multiple b values. For DCE, a single signal-intensity time curve was derived for each zone. Area under curve after two minutes (AUC<sub>120</sub>), slope of enhancement (SoE) and maximum enhancement (ME) were derived.

**Statistical analysis:** A repeated measures analysis of variance (ANOVA) followed by Dunnett's multiple comparison post-test was used to compare mp-MRI parameters at each post-biopsy timepoint against pre-biopsy values for the biopsy cohort. A paired two-tailed Student t-test was used to compare between the baseline and follow-up mp-MRI studies of the control cohort.

**Results:** There was a significant decrease of nT2 SI and T<sub>10</sub> for up to 6 month after biopsy in right and left peripheral zones of the biopsy cohort (p<0.05). No significant change of biopsy cohort transition zone's nT2 SI (p=0.10 to 0.82) and T<sub>10</sub> (p=0.76 to 1.0) was demonstrated compared with the pre-biopsy scan. Control cohort T<sub>10</sub> of both peripheral zones and transition zones demonstrated a significant reduction in follow up scan compare to baseline (p<0.05). Biopsy cohort's mean ME at 1 month post-biopsy was significantly lower within right peripheral zone (p<0.05) whilst mean AUC<sub>120</sub> was significantly higher at 1 month post-biopsy (p<0.05). In the control cohort, right transition zone AUC<sub>120</sub> was significantly higher than baseline (p<0.05). No other significant changes were demonstrated in the ME, AUC<sub>120</sub> and SoE of any other prostate zones in biopsy (p=0.06 to 1.0) and control cohorts (p=0.07 to 0.89). ADC analysis of left and right peripheral and transition zones in control cohort showed no significant changes compare to baseline at any time point (p=0.23 to 1.0)(Fig.1). There was no significant difference of ADC in any of the prostate zones in control cohort (p=0.08 to 0.62) (Fig.2).

**Discussion:** A significant decrease in T<sub>10</sub> after TRUS biopsy demonstrated in this work is consistent with the qualitative increase in T1 signal intensity reported previously [5]. Moreover the significant decrease in nT2 SI at one month post biopsy has also been reported previously [6]. However, we observed no significant changes of ADC at any time point in biopsy and control cohorts. DCE analysis demonstrated inconsistent results in right and left side of prostate. Since the biopsy should equally affect both side of the prostate gland, inconsistency in DCE results could be attributed to poor repeatability and reproducibility. Global changes in T<sub>10</sub> within the control cohort may reflect scanner drift over the longer interval between scans.

**Conclusion:** ADC is least affected in post biopsy settings and DWI could be used to localize prostate tumour even at one month post-biopsy. Moreover, the absence of significant changes in nT2SI, T<sub>10</sub> and ADC in anterior prostate gland suggests that for patients with a negative biopsy result and continued PSA elevation, reliable imaging of the anterior gland is possible as early as 1-month following biopsy in order to localize unsampled tumour.

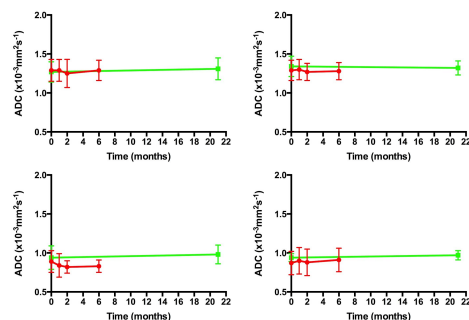


Fig.1: Temporal changes of ADC in biopsy (red) and control (green) cohort for left and right peripheral zones

Fig.2: Temporal changes of ADC in biopsy (red) and control (green) cohort for left and right transition zones

## References:

- [1]. Tamada et al.2008. Radiology; 248:531-539.
- [2]. Qayyum et al.2004. AJR; 174:1079-1083
- [3]. Ikonen et al.1998. Radiology; 42:70-73
- [4]. Roethke et al.2012.Worl J Urol; 30:213-218
- [5]. White et al.1995. Radiology; 195:385-390.
- [6]. Rosenkratz et al.2010. Magn Reson Imaging; 31:1387-1394