

## Multiparametric MR imaging for the assessment of prostate cancer aggressiveness at 3 Tesla

Eline K. Vos<sup>1</sup>, Thiele Kobus<sup>1</sup>, Geert Litjens<sup>1</sup>, Thomas Hambroek<sup>1</sup>, Christina Hulsbergen-van de Kaa<sup>2</sup>, Marnix Maas<sup>1</sup>, and Tom Scheenen<sup>1</sup>

<sup>1</sup>Radiology, Radboud university medical center, Nijmegen, Gelderland, Netherlands, <sup>2</sup>Pathology, Radboud university medical center, Nijmegen, Gelderland, Netherlands

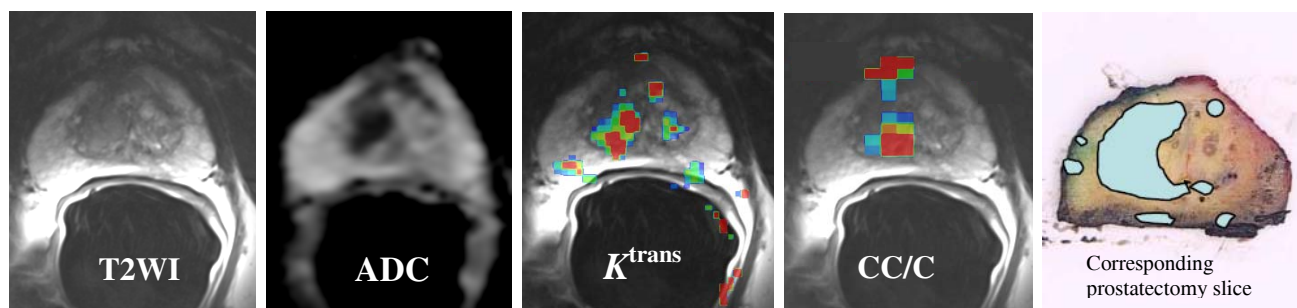
**Target audience:** (Uro-)radiologists and physicists with an interest in multiparametric MR techniques

**Introduction:** Accurate assessment of aggressiveness of localized prostate cancer (PCa) is essential, because not all PCa is life-threatening and overtreatment of indolent disease should be prevented. The different functional magnetic resonance (MR) techniques, diffusion weighted imaging (DWI) [1,2], MR spectroscopic imaging (MRSI) [3] and dynamic contrast-enhanced (DCE)-MRI [4], show potential for assessment of PCa aggressiveness. For example, this information can be used to guide targeted biopsy or focal therapy. Adding DWI to T2-weighted imaging (T2WI) is straightforward and relatively easy to acquire and interpret. On the other hand, DCE-MRI and MRSI require expertise, dedicated software programs and extensive post-processing for successful application. The purpose of this study was to evaluate whether a full multiparametric MRI (mpMRI) is useful for discriminating between significant and indolent PCa.

**Materials & methods:** The need for informed consent for retrospective use of anonymized clinical data was waived by the institutional review board. Forty-three patients who underwent a mpMRI exam (T2WI, DWI, MRSI and DCE-MRI) at 3T with an endorectal coil prior to a prostatectomy were included. Apparent diffusion coefficient (ADC) maps were calculated from DWI with b-values of 0, 50, 500 and 800 sec/mm<sup>2</sup>. Three-dimensional MRSI was acquired with a point-resolved spectroscopy sequence (TE/TR 145/750 ms) with outer volume lipid suppression and additional water and lipid suppression. Metabolite ratios (Choline+Creatine/Citrate (CC/C) and Choline/Creatine (C/C)) were calculated with Metabolite Report (Siemens, Erlangen, Germany). DCE-MRI was performed with a 3D spoiled gradient echo sequence (temporal resolution 3 sec) during intravenous injection of a Gadolinium chelate. Semi-quantitative parameters (wash-out (WO) and wash-in (WI)) were extracted from the signal intensity-time curves [5] and pharmacokinetic parameters ( $K^{trans}$  and  $K_{ep}$ ) were calculated according to the Tofts model [6].

For each patient spherical regions of interest (ROI) of the size of a spectroscopy voxel (0.37 or 0.64 cm<sup>3</sup>) were drawn in the tumor lesion on T2WI, based on whole-mount prostatectomy specimens and blinded from any functional technique. Multiple ROIs were drawn if needed to ensure coverage of the entire tumor lesion. Only tumors with a minimum volume of 0.5cc were included. The following parameters were calculated for each ROI: 25<sup>th</sup> percentile (25p) of ADC and WO; 75<sup>th</sup> percentile (75p) of WI,  $K^{trans}$  and  $K_{ep}$ ; and the CC/C ratio, the C/C ratio and the standardized threshold approach (STA) adjusted for malignancy rating [3]. Percentiles were used as it was expected that these values represent the most aberrant part of the tumor. Per tumor lesion the minimum ADC and WO, the maximum WI,  $K^{trans}$ ,  $K_{ep}$ , CC/C and C/C, and the adjusted STA were used for analysis.

PCa was classified as indolent (only Gleason grade (GG)  $\leq 3$ ) or significant (any GG  $\geq 4$  component) cancer. Peripheral zone (PZ) and transition zone (TZ) were analyzed separately. Receiver operating characteristic (ROC) curves were used to evaluate the discriminating performance between indolent and significant PCa, and the area under the ROC-curve (AUC) was determined for each parameter. Logistic regression modeling (LRM) was performed for adding DCE-parameters or MRSI parameters, or both, to ADC, and the AUC was calculated for each combination. ROC-curves for combinations of parameters were compared to the ROC-curve of ADC alone. A p-value  $<0.05$  was considered statistically significant.



Clinically significant tumor in the right transition zone with Gleason score 4+3, visible on ADC-map,  $K^{trans}$ -map, CC/C-map and prostatectomy.

**Results & discussion:** Fifty-four cancer lesions were present in 43 patients, with 40 lesions in the PZ and 14 lesions in the TZ. A brief overview of the AUCs is presented in the table. In the PZ, the ADC showed good discriminating performance for indolent versus significant PCa, with an AUC of 0.81. When adding DCE-MRI or MRSI to ADC, the AUC increased slightly for most parameters, but not significantly. This implies that there is limited additional clinical value of DCE-MRI and MRSI for the PZ.

In the TZ, the ROC-curve showed an AUC of 0.69 for ADC alone. Combining DCE-parameters and/or MRSI-parameters with ADC increased the AUC for every possible combination of parameters. When adding  $K^{trans}$  and C/C to ADC, the increase only approached significance (AUC: 0.96,  $p = 0.09$ ). The substantial increase in AUC with addition of both DCE and MRSI parameters suggests that these techniques can be helpful for discriminating between indolent and significant PCa. However, the small sample size for the TZ influences the results. A larger sample size and a prospective study design are needed to confirm these preliminary results.

### Conclusion:

The use of ADC calculated from DWI in combination with anatomical T2WI is sufficient for the assessment of PCa aggressiveness in the PZ. In the TZ, both DCE-MRI and MRSI are a useful addition to T2WI and DWI for the discrimination between indolent and significant PCa.

**References:** [1] Hambroek T, et al. 2011. *Radiology* 259(2):453-61. [2] Verma S, et al. 2011. *Am J Roentgenol* 196(2):374-81. [3] Kobus T, et al. 2012. *Radiology* 265(2):457-467. [4] Vos EK, et al. 2013. *Eur Urol* 64(3):448-55. [5] Huisman H, et al. 2001. *J Magn Reson Imaging* 13(4):607-14. [6] Tofts P, et al. 1999. *J Magn Reson Imaging* 10(3):223-32.

**Acknowledgement:** this work received funding from the European Research Council (FP7/2007-2013) / ERC Grant agreement n° [243115].

Peripheral Zone:	
ADC	AUC [95% CI]
ADC	0.81 [0.67 – 0.95]
ADC + WI	0.84 [0.71 – 0.97]
ADC + $K_{ep}$	0.81 [0.65 – 0.94]
ADC + STA	0.86 [0.75 – 0.98]
ADC + DCE + MRSI	0.83 [0.70 – 0.95]
Transition Zone:	
ADC	0.69 [0.37 – 1.00]
ADC + WO	0.71 [0.40 – 1.00]
ADC + $K^{trans}$	0.90 [0.73 – 1.00]
ADC + C/C	0.80 [0.55 – 1.00]
ADC + $K^{trans}$ + C/C	0.96* [0.92 – 1.00]
CI = confidence interval	
* approached significance ( $p = 0.09$ ), compared to ADC alone in the transition zone.	