

# STRUCTURAL MRI CORRELATES OF COGNITIVE IMPAIRMENT IN PATIENTS WITH MULTIPLE SCLEROSIS: A MULTI CENTER STUDY

Elisabetta Pagani<sup>1</sup>, Maria A. Rocca<sup>1</sup>, Paolo Preziosa<sup>1</sup>, Matteo Atzori<sup>2</sup>, Frederik Barkhof<sup>3</sup>, Nicola De Stefano<sup>4</sup>, Christian Enzinger<sup>5</sup>, Franz Fazekas<sup>6</sup>, Antonio Gallo<sup>7</sup>, Hanneke Hulst<sup>8</sup>, Laura Mancini<sup>2</sup>, Xavier Montalban<sup>8</sup>, Alex Rovira<sup>9</sup>, Maria Laura Stromillo<sup>4</sup>, Gioacchino Tedeschi<sup>7</sup>, Giancarlo Comi<sup>10</sup>, and Massimo Filippi<sup>1</sup>  
<sup>1</sup>Neuroimaging Research Unit, Institute of Experimental Neurology, San Raffaele Scientific Institute, Vita-Salute San Raffaele University, Milan, MI, Italy, <sup>2</sup>Dept. Brain Repair and Rehabilitation, Institute of Neurology, UCL, London, GB, United Kingdom, <sup>3</sup>Department of Radiology, Free University Medical Centre, Amsterdam, NL, Netherlands, <sup>4</sup>Department of Neurological and Behavioral Sciences, University of Siena, Siena, SI, Italy, <sup>5</sup>Division of Neuroradiology, Medical University of Graz, Graz, AT, Austria, <sup>6</sup>Department of Neurology, Medical University of Graz, Graz, AT, Austria, <sup>7</sup>Department of Medical, Surgical, Neurological, Metabolic and Aging Sciences, Second University of Naples, Naples, NA, Italy, <sup>8</sup>Department of Neurology-Neuroimmunology, Vall d'Hebron University Hospital, Barcelona, CT, Spain, <sup>9</sup>Department of Radiology, Vall d'Hebron University Hospital, Barcelona, CT, Spain, <sup>10</sup>Department of Neurology, San Raffaele Scientific Institute, Vita-Salute San Raffaele University, Milan, MI, Italy

**Target Audience.** Neurologists and Neuroradiologists.

**Purpose.** To apply a voxel-wise analysis to brain high-resolution T1-weighted and diffusion tensor (DT) MRI scans to assess the structural correlates of cognitive dysfunction in multiple sclerosis (MS) patients and their validity in a multicenter setting.<sup>1</sup>

**Methods.** Brain dual-echo, 3DT1-weighted, and DT MRI sequences were collected from 62 relapsing-remitting MS patients and 65 healthy controls (HC) from seven European centers. The Expanded Disability Status Scale score, RAO's neuropsychological battery and Wisconsin Card Sorting Test were assessed. Patients with  $\geq 2$  abnormal neuropsychological tests were considered cognitively impaired (CI). The distribution of GM and WM atrophy and microstructural WM damage were assessed using voxel-wise approaches.<sup>2</sup>

**Results.** No group  $\times$  center interaction was found for T2-hyperintense, T1-hypointense lesion volume, GM and WM volumes, whereas significant interaction for GM and WM DT-MRI metrics was found. Twenty-three (37%) MS patients were classified as CI. Compared to cognitively preserved (CP), CI patients had higher T2 and T1 lesion volume, and lower volumes of the whole brain, WM, GM and deep GM nuclei. From DT-MRI analysis, intrinsic damage within T2 lesions, but not damage to the WM and GM, was more severe in CI vs CP patients. Using voxel-based morphometry, compared to CP patients and HC, CI patients had atrophy of the thalami, hippocampi, several fronto-parietal GM regions (*Figure 1*) and the posterior corpus callosum (CC). Regional brain volume abnormalities were significantly correlated to neuropsychological test performance (r values ranging from -0.54 to 0.61) (*Figure 2*).

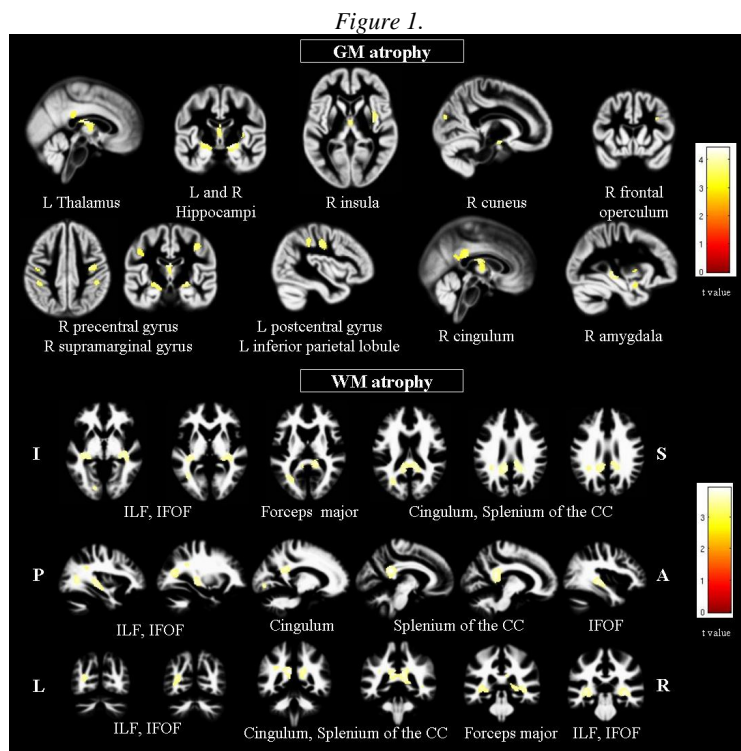


Figure 1.

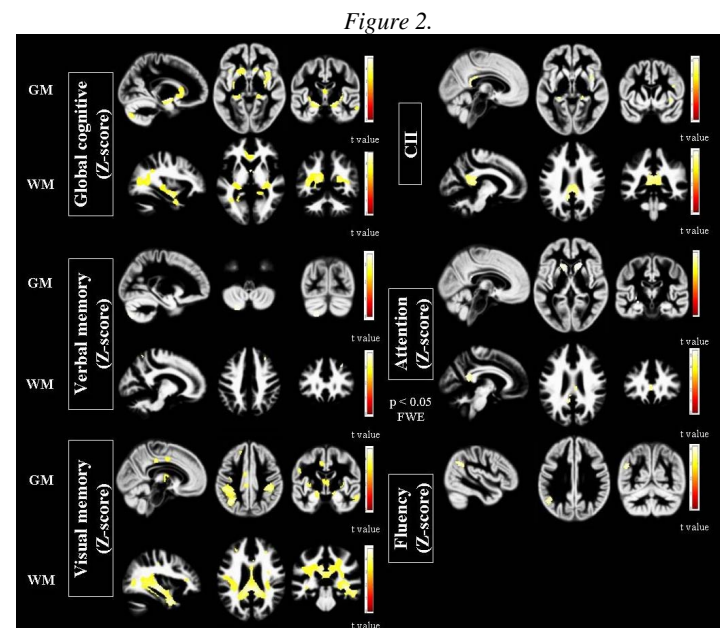


Figure 2.

Figure 1. Regions of GM and WM atrophy at the conjunction analysis between CI MS vs CP MS and HC ( $p < 0.001$  uncorrected).

Figure 2. Brain regions significantly correlated to neuropsychological test performance ( $p < 0.001$  uncorrected).

**Discussion.** The application of voxel-wise methods to define the regional distribution of brain damage in a multicenter setting in MS patients is feasible and contributes to better characterize disease manifestations, including cognitive impairment. Regional atrophy evaluation seems to be less affected than DT MRI evaluation by a multicenter set-up.

**Conclusion.** The definition of standardized protocols of acquisition and analysis of MRI data for multicentre studies is a rewarding strategy to better characterize the heterogeneous clinical manifestations of MS and my provide novel outcome measures for clinical trials.

## References.

1. Filippi M, Rocca MA, Benedict RH, et al. The contribution of MRI in assessing cognitive impairment in multiple sclerosis. *Neurology* 2010;75:2121-8
2. Ashburner J, Friston KJ. Voxel-based morphometry--the methods. *Neuroimage* 2000;11:805-21