

CORTICAL PATHOLOGY IS ASSOCIATED TO PROXIMAL UNDERLYING WHITE MATTE INJURY IN MULTIPLE SCLEROSIS: A MULTIMODAL 7T AND 3T MRI STUDY USING SURFACE BASED AND TRACT BASED ANALYSIS.

Celine Louapre¹, Sindhuja T Govindarajan², Costanza Gianni², Julien Cohen-Adad³, Revere Philip Kinkel⁴, and Caterina Mainero²
¹AA Martinos Center for Biomedical Imaging, Charlestown, MA, United States, ²AA Martinos Center for Biomedical Imaging, MA, United States, ³Institute of Biomedical Engineering Ecole Polytechnique de Montreal, QC, Canada, ⁴Beth Israel Deaconess Medical Center, MA, United States

Target audience: neuroradiologist, neurologist

Purpose: Cortical damage and diffuse normal appearing white matter (NAWM) appear to be hallmarks of physical and cognitive disability and disease progression in Multiple Sclerosis (MS)¹. Neuropathological studies have provided evidence of degenerative process (demyelination, inflammation, neuronal loss) that primarily targets the cortex, independent from white matter (WM) pathology. However, this view has been challenged by recent finding in vivo of a correlation between cortical lesion load and diffuse NAWM injury, leading to speculate that cortical lesions are implied in NAWM pathogenesis and may even drive NAWM degeneration in MS².

The aim of our study is to analyse if cortical degeneration as assessed by cortical thickness (CT) and intracortical laminar mapping of T2* relaxation decay is spatially associated with underlying WM diffuse pathology as assessed by diffusion tensor imaging (DTI). We tested the relationship between cortical degenerative markers and juxtacortical DTI abnormalities at the overall brain level on the one side, and at the tract level in terms of distance to the WM surface on the other side.

Methods: In 33 MS patients (9 early MS, 15 relapsing remitting MS, 9 secondary progressive MS), we collected on 7T: a multi-echo T2*-gradient-echo sequences (0.33x0.33x1 mm³) and on 3T: 1/ DTI images (1.85 mm iso, 60 directions) 2/ a 3D MPRAGE T1-weighted scan (0.9mm iso).

3DT1 images were used for cortical surface reconstruction, measurement of cortical thickness (CT), and co-registration with 7 T and DTI data using Freesurfer. T2* cortical decay (ms) maps were calculated voxelwise using Levenberg–Marquardt non-linear regression, registered to the cortical surfaces, and sampled 50%, and 75% depths from the pial surface (Fig.1). DTI images were processed through TRACULA pipeline in Freesurfer, allowing for reconstruction of fractional anisotropy (FA), axial diffusivity (AD) and radial diffusivity (RD) maps, that were subsequently sampled at 2 mm below the WM surface. The cortico-spinal tract (CST) and the cingulum were reconstructed and 4 successive portions were delimited, the cutting points being consistently determined by the FA profile along the tract.

Statistical analysis: We performed a General Linear Model (GLM) at the vertex by vertex level to test the relationship between 1/CT, T2* at 75 and 50% from the pial surface and 2/ FA, AD and RD at 2mm below the WM surface (p<0.05, corrected for multiple comparisons). A spearman rank correlation was performed between T2* at 75% depth in the precentral gyrus and the precuneus and DTI along the CST and cingulum respectively.

Results

1/Vertex by vertex GLM analysis

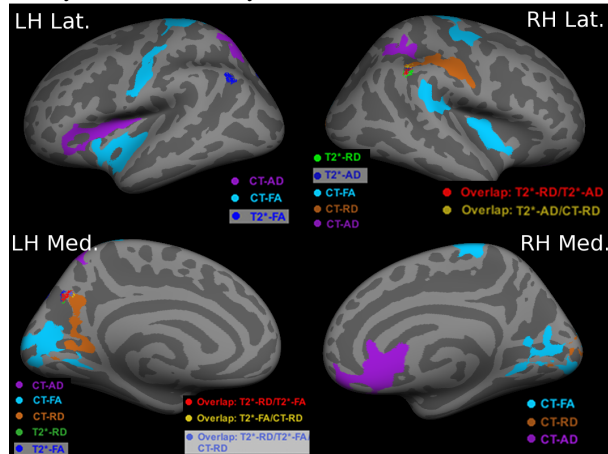


Fig. 2 Areas of correlation at the vertex level between CT decrease and DTI abnormalities, and T2* increase and DTI abnormalities. p<0.05 corrected for multiple comparisons

Discussion We found a spatial relationship between cortex and subcortical WM pathology at the overall brain level, and as a function of the depth from the white matter surface within WM tracts. Longitudinal studies will be needed to determine if cortical degenerative process can drive underlying WM pathology and vice versa.

References

- 1.Kutzelnigg A and Lassmann H. Cortical demyelination in multiple sclerosis: a substrate for cognitive deficits? *J Neurol Sci.* 2006; 245: 123-6.
- 2.Mistry N, Abdel-Fahim R, Mougin O, Tench C, Gowland P and Evangelou N. Cortical lesion load correlates with diffuse injury of multiple sclerosis normal appearing white matter. *Mult Scler.* 2013. Jul 15

Funding: NMSS RG 4281-A-1; NIH RO1 R01NS078322-01A1; ARSEP

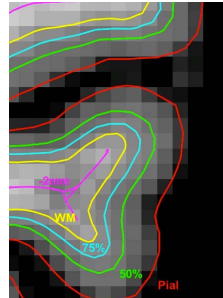


Fig.1: Surfaces sampled using freesurfer (-2mm below the WM surface, 50% and 75% depth from the pial surface)

CT decrease and T2* increase at 75% depth correlates with DTI abnormalities (decreased FA, increased AD and RD) in the postcentral gyrus, supramarginal gyrus and precuneus mainly (Fig. 2). T2* at 50% depth does not correlate with any of the DTI metrics.

2/ Intracortical T2* increase at 75% depth from the pial surface correlates with DTI metrics abnormalities along its corresponding tract, only for the two most proximal portions.

Precentral T2* vs CST			Precuneus T2* vs Cingulum		
	p	rho		p	rho
AD1	0.02	0.27	FA1	0.0003	-0.42
AD2	0.03	0.26	FA2	0.0007	-0.40
			RD1	0.0008	0.40
			RD2	0.0010	0.37