

Assessment of the response of colorectal tumours to imatinib mesylate therapy using carbogen and hypercapnia gas challenges

Miguel R. Goncalves^{*1}, Simon Walker-Samuel^{*1}, Rajiv Ramasawmy^{1,2}, Sean P. Johnson², R. Barbara Pedley², and Mark F. Lythgoe¹

¹UCL Centre for Advanced Biomedical Imaging, Division of Medicine, London, United Kingdom, ²UCL Cancer Institute, London, United Kingdom

^{*}joint first authors

Target audience: Researchers interested in cancer imaging, particularly in the effects of drug therapy on the tumour microenvironment.

Introduction: Hypoxia and impaired blood flow are characteristics of solid tumours, which result from their rapid rate of proliferation and inefficient vascular architecture [1,2]. Tumour hypoxia has been shown to cause resistance to radiotherapy [3], while poor blood flow impacts negatively on the delivery of chemotherapeutic agents [4]. Gradient-echo MRI has been used to study tumour vascular responsiveness to hyperoxia (by breathing high oxygen content gases) and hypercapnia (by breathing high carbon dioxide content gases), via changes in T_2^* [5]. Additionally, T_1 measurements have been employed to assess tumour tissue oxygenation [6]. Imatinib mesylate is an antiangiogenic drug that reduces the density of immature vessels and is thought to temporarily improve the integrity and function of the remaining vasculature [7]. Given the effect of imatinib on tumour vasculature, we aimed to study its effect on colorectal tumour responsiveness to carbogen (95% O_2 , 5% CO_2) and hypercapnia (air + 5% CO_2) vascular challenges.

Methods: *Tumour models and MRI:* 5×10^6 LS174T ($n=12$) colorectal carcinoma cells were injected subcutaneously into CD1 *nu/nu* mice. After tumours had grown to an approximate volume of 350mm^3 , a baseline MRI scan was performed on a 9.4T Agilent VNMRs 20cm horizontal-bore system, with a 39mm birdcage coil. Two sets of data were acquired. The first acquisition was a 40-minute dynamic multi-slice, multi-gradient echo (GEMS) sequence, during which a series of gas challenges were administered, each of 10 minutes duration: air, carbogen (95% O_2 , 5% CO_2), air and air + 5% CO_2 . Changes in signal intensity (SI) and R_2^* ($=1/T_2^*$), relative to air-breathing phases were measured. GEMS sequence parameters: $TR=59.62\text{ms}$, 5 echoes, $TE_1=2\text{ms}$, echo spacing=2ms, 5 slices, 64×64 matrix, voxel volume $312 \times 312 \times 1500\mu\text{m}$, $FA=20^\circ$. The second scan was a Look-Locker segmented Inversion Recovery sequence, from which two R_1 ($=1/T_1$) values were calculated, one during air breathing and the other during carbogen breathing. Anaesthesia was maintained using isoflurane (1.5%) and normothermia was maintained using piped warm water. Look-Locker sequence parameters: $TR=10\text{s}$, 50 TIs, TI spacing=110ms, $TR_{RF}=2.3\text{ms}$, $TE=1.18\text{ms}$, 5 slices, 128×128 matrix, voxel volume $78 \times 78 \times 1500\mu\text{m}$, $FA=8^\circ$.

Therapy protocol: Imatinib was administered orally (100mg/kg) immediately after a baseline scan (day 0) and then each day for five consecutive days ($n=9$). MRI scans were performed at days 0, 3 and 5. Animals in the control group were treated with saline ($n=3$). Daily calliper measurements were taken to assess tumour growth rate.

Post processing: Voxel-wise post processing included: **i)** R_2^* maps of the difference between carbogen and air breathing (ΔR_2^*), to estimate blood oxygenation changes. **ii)** R_1 maps showing the difference between carbogen and air breathing (ΔR_1), to estimate tissue oxygenation changes. **iii)** Signal intensity (SI) maps of the difference between air + 5% CO_2 and air breathing (ΔSI). A paired Wilcoxon signed rank test was used to compare between days of treatment.

Results: We observed no growth rate differences in LS174T tumours between imatinib-treated and control groups, as previously observed [8]. Mouse #9 from the treated group was sacrificed before day 5 due to tumour ulceration and mouse #3 from the control group was excluded from analysis due to time-varying susceptibility imaging artifacts. Figure 1a shows an example tumour R_2^* response to carbogen, which is regionally heterogeneous; a negative ΔR_2^* might be expected with carbogen breathing (hyperoxia), due to the decrease in paramagnetic deoxyhaemoglobin, whilst ΔR_1 (data not shown) could be expected to be positive due to increased dissolved paramagnetic tissue oxygen. However, tumours showed some regions with increases in R_2^* and/or R_1 , alongside other regions with decreases in one or both parameters (Figure 1a). No significant change in median ΔR_2^* or ΔR_1 was observed with imatinib treatment, although the standard deviation (SD) of ΔR_2^* values within tumours significantly increased between day 0 and 5 (Figure 1b). Figure 2a illustrates the SI change ($TE=6\text{ms}$) following hypercapnia (air + 5% CO_2), in one example tumour. The SD of ΔSI also significantly decreased between day 0 and day 3 (Fig.2b).

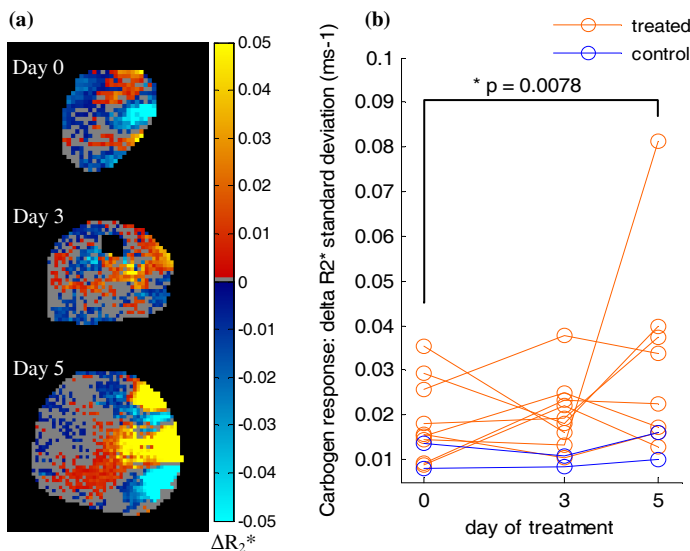


Figure 1 – R_2^* response to carbogen challenge. (a) Example tumour ΔR_2^* (grey areas represent non-significant response ($p > 0.05$)). (b) Group analysis of ΔR_2^* spatial heterogeneity (standard deviation).

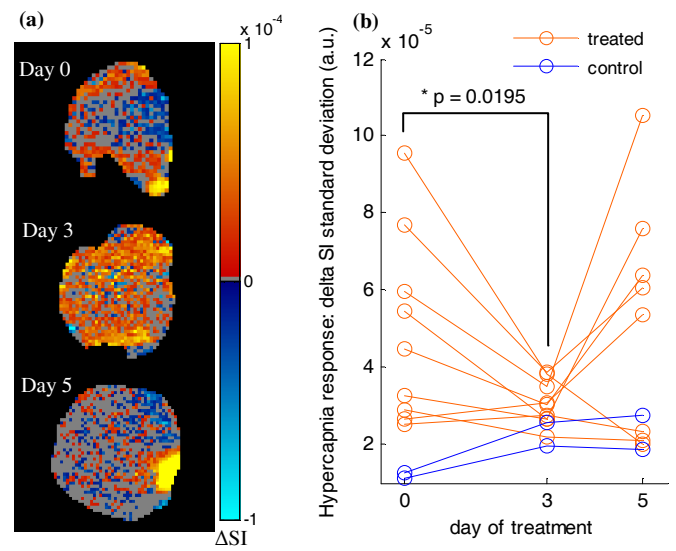


Figure 2 – Signal intensity response to hypercapnia (air+5% CO_2). (a) Example tumour ΔSI (grey areas represent non-significant response ($p > 0.05$)). (b) Group analysis of ΔSI spatial heterogeneity (standard deviation).

Discussion & Conclusion: We have presented a therapy study into the effects of an antiangiogenic agent, imatinib mesylate, in the LS174T colorectal tumour xenograft model. We observed an increase in the heterogeneity of ΔR_2^* during carbogen breathing (hyperoxia), at 5 days following treatment and a decrease in the heterogeneity of ΔSI during hypercapnia at day 3. Imatinib is known to decrease vessel density [7] and interstitial fluid pressure in LS174T tumours [8], potentially leading to a regional ‘normalising’ of the vasculature (i.e. regional improvement of vascular integrity and function). This effect could increase the tumour’s capacity for oxygen transport (leading to a greater negative ΔR_2^*), but also the potential for vascular steal effects, (causing a greater positive ΔR_2^*). A combination of these effects could therefore explain the increased heterogeneity in the observed R_2^* response to hyperoxia. Imatinib has also been shown to reduce pericyte coverage in LS174T tumours [7], and this could cause a regional decrease in response to hypercapnia (via loss of muscle tone and a smaller positive ΔSI). This could also be accompanied by associated vascular steal from regions still responsive to hypercapnia, thereby potentially reducing the heterogeneity in ΔSI at day 3. Thus, gradient echo MRI alongside a gas challenge could offer a method to investigate ‘windows’ in which to apply secondary therapies after antiangiogenic drug therapy.

Acknowledgements: This work was carried out as part of King’s College London and UCL Comprehensive Cancer Imaging Centre CR-UK & EPSRC, in association with the MRC, DoH and British Heart Foundation (England). **References:** [1] Dewhirst M, *Radiation Res.* 172:653-65. [2] Patan S *et al.*, *Microvasc. Res.* 51:260-72. [3] Gray L *et al.*, *Br. J. Radiol.* 26:638-48. [4] Durand R *et al.*, *Cancer and Metastasis Rev.* 20:57-61. [5] Baudalet C *et al.*, *NMR Biomed.* 19:69-76. [6] Burrell J, *et al.*, *J. Magn. Reson. Imag.* 38:429-34. [7] Rajkumar V *et al.*, *Tumor Biol.* 33:2019-29. [8] Baranowska-Kortylewicz J, *Cancer Res.* 65:7824-31.