

# Transperineal in-bore 3T MRI guided prostate biopsy in active surveillance patients: Higher prevalence of anteriorly located positive prostate cancer targets

Tobias Penzkofer<sup>1,2</sup>, Kemal Tuncali<sup>1</sup>, Fiona M Fennessy<sup>1,3</sup>, Junichi Tokuda<sup>1</sup>, Andriy Fedorov<sup>1</sup>, Sang-Eun Song<sup>1</sup>, Nobuhiko Hata<sup>1</sup>, and Clare M Tempany<sup>1</sup>  
<sup>1</sup>Radiology, Brigham and Women's Hospital, Boston, MA, United States, <sup>2</sup>Diagnostic and Interventional Radiology, RWTH Aachen University Hospital, Aachen, Germany, <sup>3</sup>Radiology, Dana Farber Cancer Institute, Boston, MA, United States

**Target audience:** Body MRI, Abdominal/GU, Interventional Radiologists

**Purpose:** Prostate cancer (PCa) localization within the gland is known to influence the success rate of transrectal ultrasound (TRUS) guided prostate biopsy; anteriorly located lesions are at risk to be missed or undergraded (1). The decision for a patient to enroll in an active surveillance (AS) protocol is based on age, PSA, histopathological grading based on TRUS-acquired specimens and patient preferences. Transperineal MRI-guided techniques might have an advantage to avoid undergrading in this setting. This study was designed to assess the influence of target localization on positivity rate in lesions biopsied using in-bore, transperineal MRI-guided prostate biopsy (tpMRGB) in a cohort of patients considering or on active surveillance.

**Methods:** The study was approved by the local ethics committee and 20 transperineal in bore, 3T MRI-guided prostate biopsies were performed in 20 patients. All men had a pre-biopsy 3T endorectal coil multiparametric MR (mpMRI) exam. All men had at least one lesion suspicious for cancer on mpMRI. Patient demographics were: mean age  $65.5 \pm 6.5$  years ( $\pm$  stddev), mean PSA value  $7.6 \pm 5.3$  ng/dl, mean prostate volume  $59.1 \pm 21.1$  ml and mean PSA density  $0.16 \pm 0.16$  ng/ml<sup>2</sup>. Positive tpMRGB biopsy rates and cancer aggressiveness, based on Gleason scores (GS) were analyzed and statistically compared. All patients had prior cancer diagnosis and were either on active surveillance or considering AS based on a TRUS-guided biopsy showing GS 3+3 (18 patients) or low volume GS 3+4 cancer (2 patients).

**Results:** 20 men had successful tpMRGB with an average of  $3.6 \pm 1.6$  targets per gland were biopsied, a total of 72 suspicious foci. Biopsy was positive for cancer in 14 (70.0%) men based on 20 positive targets (27.8% of 72). Eleven of the patients (55.0%) had a high grade cancer (Gleason 3+4 or higher). Ten patients were upgraded on biopsy outcome (50.0%); one patient already had known Gleason 3+4 before undergoing the biopsy. The majority of the targets were located in the posterior (34 of 72, 47.2%, Figure 2) and central parts of the prostate (24 of 72, 33.3%), 14 targets were in the anterior part (19.4%). Cancer rates were 71.4% (anterior), 12.5% (central), and 20.6% (posterior), with a significantly higher rate in the anterior gland ( $p=0.0002$ ). Overall, 57.1% of the biopsies in the anterior zone resulted in high grade or recurrent PCa, compared to only 12.1% in the rest of the gland ( $\chi^2$ :  $p=0.0008$ ). In relation to the positive biopsies, 80.0% of PCa found in the anterior gland were high grade or recurrent PCa, 70.0% in the rest of the gland ( $p>0.05$ ).

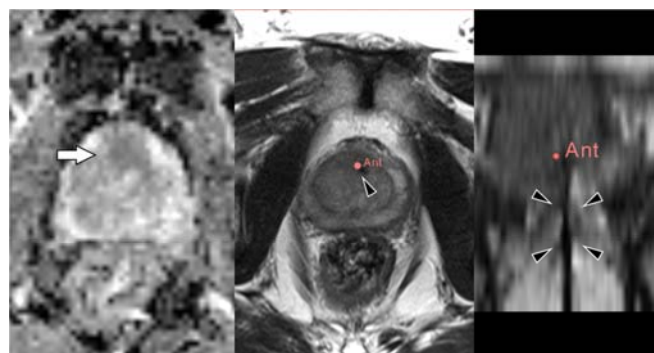
**Discussion:** Transrectally performed biopsy techniques preferentially target posterior regions of the prostate (1). Using in-bore transperineal MRI-guided prostate biopsy, with pre-biopsy mpMR, we found a significantly higher proportion of positive biopsies in the anterior part of the gland, through an average of 3.6 targeted biopsies per prostate. This suggests that tpMRGB offers an advantage, allowing targeted access to the anterior prostate. Similar observations have been demonstrated in template mapping biopsy approaches, which typically involve 30 or more cores (2, 3). These data coupled with increasing role of mpMRI, could impact decision making in the active surveillance setting.

**Conclusion:** Anterior prostate gland targets have higher cancer yields than any other location in the gland. This biopsy approach should be considered when mpMRI detects suspicious lesions in men on active surveillance.

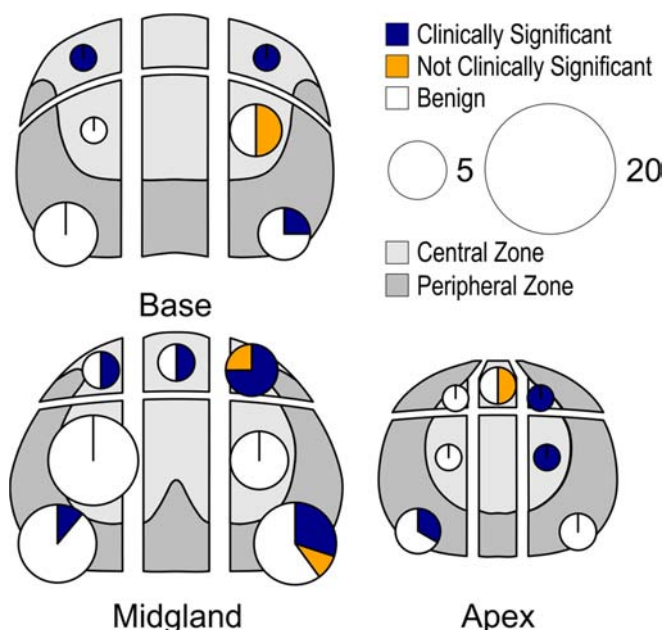
**Acknowledgements:** This work is supported by NIH P41EB015898, NIH R01CA111288, and NIH U01CA151262. Its contents are solely the responsibility of the authors and do not necessarily represent the official views of the NIH. TP received funding from RWTH Aachen University Hospital.

## References:

1. Lecornet E, Ahmed HU, Hu Y, et al. Journal of urology. 2012;188(3):974-80.
2. Vyas L, Acher P, Challacombe B, et al. BJU international. 2013.
3. Ekwueme K, Simpson H, Zakhour H, Parr NJ. BJU international. 2013;111(8):E365-73.



**Figure 1** Transperineal MRI guided prostate biopsy of an anterior zone lesion in a patient on active surveillance with elevated PSA at 21.3 ng/dl and TRUS-guided biopsy Gleason grade of 3+3. MRI shows a diffusion-restricted lesion in the anterior part of the prostate (left, white arrow). The patient underwent MRI guided transperineal prostate biopsy (middle: axial T2-weighted, right: sagittal T2-weighted, needle artifact: black arrowheads). Histopathology showed a Gleason 4+5 cancer, 20% of one core. The patient was subsequently scheduled for radical prostatectomy.



**Figure 2** Distribution of positive prostate cancer targets per prostate region including rates of clinically significant ( $>$ Gleason 3+4, blue) and low grade (Gleason 3+3, orange) PCa. The area of the pie-charts scales to the number of biopsies taken in the specific region (see legend).