

# Highly Accelerated Free-breathing ECG-Triggered Contrast-Enhanced Pulmonary Vein Angiography with Isotropic Spatial Resolution

Sébastien Roujol<sup>1</sup>, Murilo Foppa<sup>1</sup>, Tamer A. Basha<sup>1</sup>, Mehmet Akçakaya<sup>1</sup>, Kraig V. Kissinger<sup>1</sup>, Beth Goddu<sup>1</sup>, Sophie Berg<sup>1</sup>, Warren J. Manning<sup>1,2</sup>, and Reza Nezafat<sup>1</sup>  
<sup>1</sup>Department of Medicine, Beth Israel Deaconess Medical Center / Harvard Medical School, Boston, MA, United States, <sup>2</sup>Department of Radiology, Beth Israel Deaconess Medical Center / Harvard Medical School, Boston, MA, United States

## Target Audience

Scientists and clinicians who are interested in acceleration technique and pulmonary vein MR-angiography.

## Purpose/Introduction

Pulmonary vein isolation (PVI) has evolved as an accepted treatment of paroxysmal atrial fibrillation<sup>1</sup>. Contrast-enhanced pulmonary vein MR-angiography (CE-PV MRA) is commonly performed before PVI procedures to assess PV anatomy. Road maps of the left atrium and the PVs are then generated and used as road map to guide the ablation procedure. CE-PV MRA is often performed after the procedure to detect potential post-procedural complications such as PV stenosis. CE-PV MRA is clinically acquired within a prolonged breath-hold at contrast arrival in the PVs. This sequence is not ECG triggered and can lead to motion-induced blurring artifacts and over-estimation of the PV size<sup>2</sup>. In addition, this sequence requires an accurate initiation at contrast arrival in the PVs which may fail in some patients. Therefore, an improved PV-MRA protocol is desirable. In this study, we sought to investigate the feasibility of a highly-accelerated ECG-triggered CE-PV MRA with isotropic spatial resolution using compressed sensing (CS).

## Materials and Methods

All images were acquired on a 1.5 T Phillips Achieva scanner (Philips Healthcare, Best, The Netherlands) using a 32-channel cardiac phased array receiver coil.

**Highly-accelerated ECG-triggered CE-PV MRA:** To enable prospective CS acquisition, a prospective random undersampling pattern was implemented, to fully sample the k-space center lines and to randomly discard outer k-space lines<sup>3</sup>. A radial ordering was used to minimize the k-space jumps and reduce eddy current artifacts<sup>3</sup>. The proposed ECG-triggered MRA sequence used an inversion recovery, respiratory navigated (gating window=7 mm, tracking factor=0.4) SSFP sequence (TR/TE/ $\alpha$ =4.1 ms/2 ms/90°, FOV=340×340×110 mm<sup>3</sup>, spatial resolution=1.5×1.5×1.5 mm<sup>3</sup>, fat saturation, acquisition window=140 ms at mid diastole and CS acceleration factor=5). CS data were reconstructed offline using an improved B<sub>1</sub>-weighted CS reconstruction technique<sup>4</sup> which iteratively alternate between thresholding of the combined coil image using LOST<sup>3</sup> and enforcement of data consistency.

**Study design:** Nineteen patients (59±13 y, 11M) referred for clinical CMR exams were recruited. Each subject was scanned using a 1) conventional first-pass non ECG-triggered CE-PV MRA sequence and 2) the proposed accelerated ECG-triggered MRA sequence. Each subject underwent the following imaging protocol. A real time SSFP sequence was acquired during the injection of Gd-BOPTA (0.1 mmol/kg) to track the bolus contrast. The sequence was immediately stopped at contrast arrival in the right ventricle and was followed by breath hold instructions and the clinical non ECG-triggered MRA GRE sequence (TR/TE/ $\alpha$ =3.2 ms/1.1 ms/40°, FOV=320×320×90 mm<sup>3</sup>, spatial resolution=1.5×1.5×1.5 mm<sup>3</sup>, and SENSE factor=3.75). Subsequently, a Look Locker sequence was acquired to identify the optimal inversion time to null the myocardium. The proposed ECG-triggered MRA sequence was finally acquired using this selected inversion time.

**Data Analysis:** Subjective qualitative analysis was performed by an experienced cardiologist blinded from the acquisition scheme. Overall image quality and PVs' sharpness were individually scored using a 4-point scale (1:poor; 4:excellent) and compared using Wilcoxon signed rank test. Diagnostic value was also assessed as a yes/no choice and compared using McNemar's test.

## Results

Figures 1 and 2 show images acquired with the conventional and the proposed CE-PV-MRA sequences in two patients. The conventional CE-PV-MRA sequence led to blurring artifacts and poor image quality in both patients that was induced by the presence of strong motion (Figure 1a) and inaccurate timing of the acquisition (Figure 2a). The proposed approach shows substantially improved image quality and PVs sharpness in both cases (Figures 1b and 2b). Over all subjects, there was a tendency towards increased overall image quality (3.32±0.94 vs. 3.53±0.77) and improved PVs sharpness (3.0±1.0 vs. 3.42±0.83) using the proposed sequence.

## Conclusions

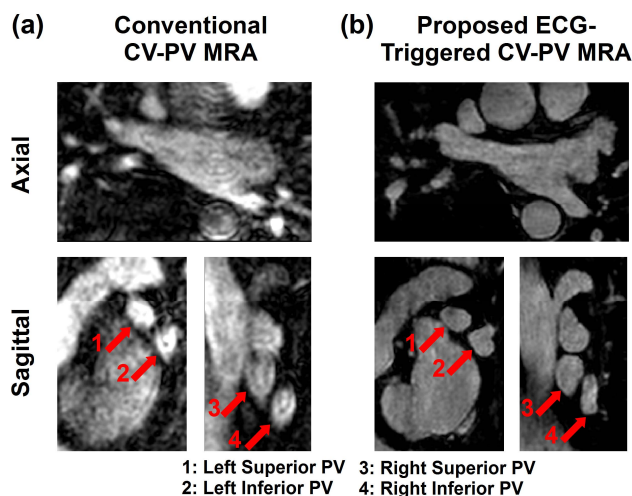
The feasibility of a highly-accelerated free-breathing ECG-triggered CE-PV MRA acquisition is shown. This technique may be a valuable alternative for patients in which the first pass CE-PV MRA fails due to inaccurate first pass timing or inability of the patient to perform a 20-25 seconds breath-hold.

## Acknowledgements

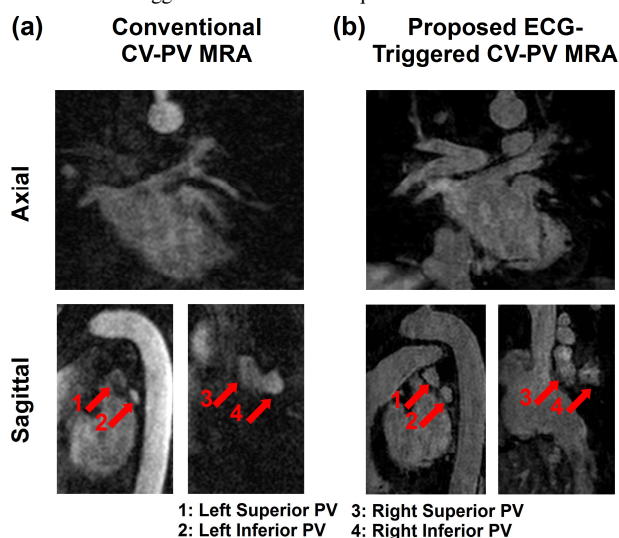
The authors acknowledge grant support from NIH R01EB008743-01A2.

## References

- [1] Ames *et al.*, Circulation, 2006
- [2] Hauser *et al.*, Am Heart J, 2006
- [3] Akçakaya *et al.*, MRM, 2011
- [4] Akçakaya *et al.*, MRM, 2013



**Figure 1.** Conventional and proposed CE-PV MRA obtained in a 63 year-old patient, referred to CMR for assessment of PV/LA anatomy prior to PVI. The conventional CE-PV-MRA sequence led to blurring artifacts. PVs sharpness and image quality were substantially improved with the ECG-triggered CE-PV-MRA sequence.



**Figure 2.** Conventional and proposed CE-PV MRA sequences acquired in a 48 year-old patient, referred to CMR for assessment of PV/LA anatomy prior to PVI. Low contrast and poor image quality were obtained with the conventional CE-PV MRA sequence due to inaccurate acquisition timing. Improved PVs sharpness and image quality were achieved using the proposed ECG-triggered CE-PV-MRA sequence.