

Pulmonary MRA: Differentiation of pulmonary embolism from Gibbs artifact

Peter Bannas^{1,2}, Mark L Schiebler¹, Utaroh Motosugi¹, Christopher J Francois¹, Scott B Reeder^{1,3}, and Scott K Nagle^{1,3}

¹Department of Radiology, University of Wisconsin, Madison, Madison, WI, United States, ²Department of Radiology, University Medical Center Hamburg-Eppendorf, Hamburg, Hamburg, Germany, ³Department of Medical Physics, University of Wisconsin, Madison, Madison, WI, United States

Target Audience: Physicists and clinicians interested in pulmonary MRA.

Purpose: Central signal intensity dropout within pulmonary arteries due to Gibbs ringing artifact can be mistaken for emboli on pulmonary MRA. This can lead to false-positive interpretation and degrade the diagnostic accuracy for pulmonary embolism (PE)¹⁻³. We propose a quantitative approach to differentiate between Gibbs ringing artifact and true PE for pulmonary MRA.

Methods: A prospective IRB-approved study was performed. 28 patients (15 female, 13 male; median age 51.5 years; range 21-91 years) who underwent pulmonary CTA for suspected PE were recruited for an additional pulmonary MRA. Signal dropouts within the pulmonary arteries that persisted on both first-pass and steady state MRA were identified and recorded. The percentage of signal loss between the vessel lumen and the dropout was calculated. CTA performed within a median of 23.5 hours prior to MRA served as the reference standard and demonstrated pulmonary embolism in 19 (68%) patients.

Results: A total of 65 vessels with low central signal intensity were identified on MRA. A median of 2 vessels with low central signal intensity (range 1 – 3) were detected per patient. 18 (28%) of the signal drops were located in lobar arteries and 47 (72%) in segmental arteries. 48 (74%) corresponded to artifacts and 17 (26%) to true PE as confirmed by CTA.

Gibbs artifacts revealed a significantly lower median signal drop of 26% (range 12-58%) and 26% (range 11-55%) as compared to PE with 85% (range 53-91%) and 77% (range 47-89%) (both $p < 0.0001$) at first-pass and steady state MRA, respectively (Figure 1). However, not all signal intensity drops of Gibbs artifact and pulmonary embolism showed such evident and marked differences. Figure 2 illustrates an example of a true pulmonary embolism with relatively small signal drop during both the first-pass MRA (57%) and in steady state MRA (52%).

ROC analyses (AUC=0.996 and 0.991, respectively) revealed a cut-off value of 53% (first-pass) and 42%-signal drop (steady state) to differentiate between Gibbs artifact and PE with a sensitivity of 100% for both and a specificity of 94% for first-pass and 92% for steady state MRA (Figure 3).

Discussion: Gibbs artifact can lead to central low signal intensity, mimicking pulmonary embolus. Quantitative analysis of this central signal dropout can be used to differentiate artifact from true PE. Our study revealed that the median value of observed %-signal drop for Gibbs artifact is significantly lower (26%) than true pulmonary embolism (85% at first-pass and 77% at steady state). However, our results demonstrated significant overlap in the signal dropout between artifact and true PE. In some cases the measured signal drop of Gibbs artifact may be larger than expected and the signal drop from pulmonary embolism may be smaller than expected. This creates a potential diagnostic dilemma if an embolus is centrally localized in the pulmonary vessel as illustrated in Figure 2. ROC curve analyses allowed us to establish a cut-off value of 53% signal intensity dropout at first pass MRA and 42% at steady state MRA for correct identification of pulmonary embolism with 100% sensitivity and >90% specificity, using CTA as a reference standard.

Conclusion: Based on the results of our study we recommend using quantitative assessment of central signal dropout as an adjunct in the diagnosis of pulmonary embolism with MRA for equivocal cases.

References: 1. François CJ. JMRI 2013; 37: 1290-1300; 2. Schiebler ML. JMRI 2013; 38: 914-925; 3. Kalb B. Radiology; 2012 263: 271-278

Acknowledgement: The authors wish to thank GE Healthcare, Bracco Diagnostics and the R&D fund, Department of Radiology, University of Wisconsin for their support.

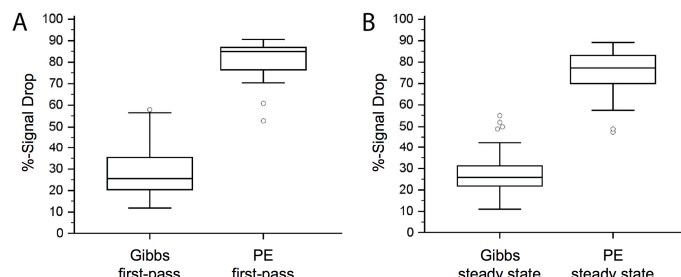


Figure 1: Pulmonary emboli lead to much higher signal drop (%) than Gibbs artifact at first-pass (A) and steady state MRA (B). However, as shown in the box-plots, there is some overlap between artifact and true PE.

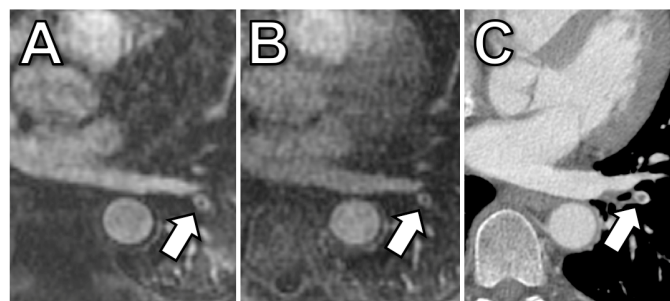


Figure 2: 42-year old women with confirmed PE. First-pass MRA (A), steady state MRA (B) and corresponding CT (C). The central signal drop in a left lower lobe segmental pulmonary artery (arrow) corresponded to a true pulmonary embolus as confirmed by CT. Signal dropout was 57% at first-pass and 52% at steady state MRA. Of note, this embolus was the only one that was detected in this patient and may have easily been mistaken for a Gibbs artifact due to its central localization within the vessel and relatively small signal intensity drop.

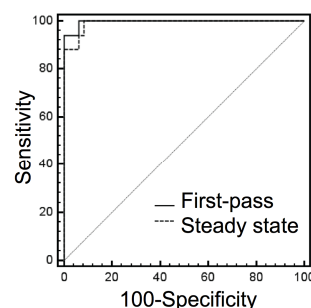


Figure 3: Comparison of Receiver operating characteristic (ROC) analysis. Graphs show a slightly larger area under the curve (AUC) for %-signal drop at first-pass MRA (AUC = 0.996, 95%-CI = 0.938-1.000) as compared to steady state MRA (AUC = 0.991, 95%-CI = 0.929-1.000); however, this difference is not statistically significant ($p=0.449$).