

VALIDATION OF A MULTIPLE-ECHO DSC-MRI APPROACH WITH T1 AND T2* LEAKAGE CORRECTION FOR BRAIN TUMOR PERFUSION IMAGING

Ashley M Stokes^{1,2}, Natenael Semmineh^{1,3}, and C. Chad Quarles^{1,2}

¹Institute of Imaging Science, Vanderbilt University, Nashville, TN, United States, ²Radiology and Radiological Sciences, Vanderbilt University, Nashville, TN, United States, ³Physics and Astronomy, Vanderbilt University, Nashville, TN, United States

Target Audience: This study is targeted toward researchers interested in the development of advanced perfusion imaging methods.

Purpose: Previous studies have shown that DSC-MRI based CBV values corrected for gadolinium contrast agent (CA) leakage are correlated with glioma tumor grade.¹ Depending on the leakage mechanism – T₁ and/or T₂* – the uncorrected CBV may be either underestimated (T₁ leakage) or overestimated (T₂* leakage). Various leakage correction strategies have been proposed¹⁻³, although few have been validated against a reference standard with the exception of CBV estimates using the Weisskoff correction for T₁ based leakage effects.⁴ Here, we propose a new strategy to correct for T₂* leakage effects on T₁-insensitive dual echo ΔR_2^* derived time series. As we have previously shown⁵, ΔR_2^* can be modeled as the sum of the intra- and extravascular ΔR_2^* components, scaled by their respective CA relaxivity values. If we assume that the dual-echo derived T₁ changes are equal to $v_e \cdot C_e(t)$, we can estimate the extravascular CA relaxivity using the transverse relaxivity at tracer equilibrium $r_{2,e}^*$ (TRATE) and then subtract T₂* leakage effects from the acquired ΔR_2^* time series, as shown in Eq. 1. This strategy was tested in a 9L rat tumor model known to exhibit both T₁ and T₂* leakage effects. For validation, we compared uncorrected and corrected CBV, CBF, and MTT against reference values obtained with an intravascular iron oxide CA.

$$\Delta R_{2,TRATE}^*(t) = \Delta R_2^*(t) - r_{2,e}^* \cdot v_e \cdot C_e(t)$$

Equation 1: TRATE ΔR_2^* corrections.

Methods: 9L gliosarcoma cells were implanted in Fischer rats (n=3), and MRI was performed at 4.7T (Agilent) at 22 days. Intravenous catheters were inserted for contrast administration with Gd-DTPA and MION. Pre-contrast T₁ maps were acquired using an inversion recovery technique (TR=8s, TE=2.9ms, 8 TI from 0.25s to 6s, FA=15°). A dual echo DSC sequence (TR=1s, TE1=8.6ms, TE2=35.0ms, 1000 repetitions) was used. After 80s of baseline images, 0.4 mmol/kg Gd-DTPA was injected. At 30 minutes after Gd-DTPA injection, 3 mg Fe/kg MION was injected. The MION injection was diluted to provide an equal volume as the Gd-DTPA injection. The dual echo tissue ΔR_2^* was calculated from TE1 and TE2. The Weisskoff (applied to TE2) and TRATE (calculated as shown in Equation 1) corrections were used to compute CBF, CBV, and MTT.

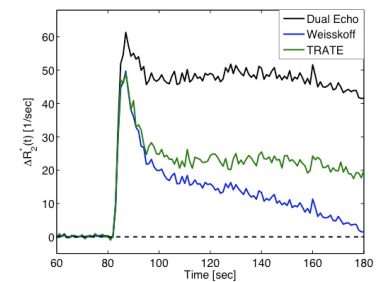


Figure 1: Tumor ΔR_2^* curves.

Results: Figure 1 shows the ΔR_2^* curves for tumor tissue using dual echo and the Weisskoff and TRATE corrections. The calculated CBF and CBV maps are shown in Figure 2, with the MION reference values in the far right column. Figure 3 shows bar plots for tumor CBF and CBV using each ΔR_2^* curve against the MION values.

Discussion: The dual echo ΔR_2^* signal is insensitive to T₁ leakage but shows clear T₂* leakage effects, leading to inflated ΔR_2^* values and overestimated CBV. Interestingly, the dual echo CBF values were not substantially different than those derived from MION. The Weisskoff and TRATE corrections led to reduced ΔR_2^* values and CBV values that were closer to the MION reference values, but both underestimated CBF. It should be noted that the Weisskoff model assumes an identical MTT between the reference and corrected tissue, which may lead to inaccurate hemodynamic estimates.⁶ In 9L tumors, the Weisskoff model likely performs reasonably well due to the similarity between tumor and normal tissue MTTs (5.2 vs. 4.6 sec, respectively). Conversely, because the TRATE correction is based on voxel-wise measures of $v_e \cdot C_e(t)$, it is insensitive to MTT differences and should be more accurate in more heterogeneous human tumors.

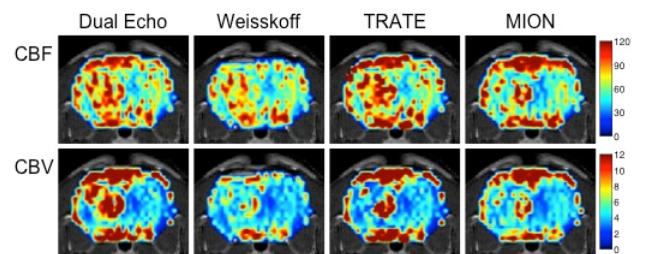


Figure 2: CBF and CBV maps from dual echo, Weisskoff and TRATE corrections, and MION reference.

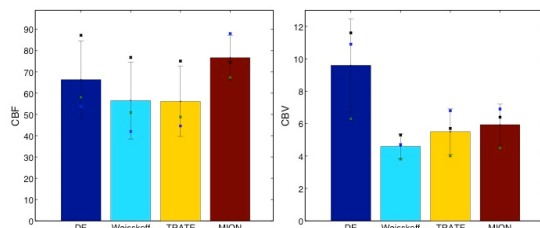


Figure 3: CBF and CBV in 9L tumors comparing dual echo, Weisskoff, and TRATE corrections to the MION reference values.

Conclusions: The DSC ΔR_2^* signals in leaky tissues, e.g. tumors, must be corrected for leakage to produce accurate CBF and CBV maps. Future work in this study is ongoing and will aim to apply these and other corrections in more animals.

- References:** 1. Boxerman JL, et al. Am J Neuroradiol (2006) 27(4):859.
2. Bjornerud A, et al. J Cereb Blood Flow Metab (2011) 31(10):2041.
3. Schmiedeskamp H, et al. J Cereb Blood Flow Metab (2013) 33(5):732.
4. Boxerman JL, et al. AJNR Am J Neuroradiol (2012) 33(6):1081.
5. Quarles CC, et al. Phys Med Biol (2009) 54(19):5749.
6. Quarles CC, et al. Magn Reson Med (2005) 53(6):1307.