

Analysis of multiparametric microvascular MRI in tumor patients using a model-based cluster approach.

Julien Bouvier¹, Nicolas Coquery¹, Sylvie Grand², Thomas Perret¹, David Chechin³, Irene Tropres¹, Alexandre Krainik¹, and Emmanuel L Barbier¹

¹U836, INSERM, Grenoble, France, France, ²Department of neuroradiology and MRI, CHU de Grenoble, France, France, ³Philips Healthcare, Suresnes, France, France

Introduction

In clinical monitoring of brain tumors, Perfusion Weighted Imaging (PWI) contributes to tumor grading and to assess the response to treatment [1]. Beyond tumor perfusion, tumor hypoxia determines the response of various therapeutic approaches including radiotherapy. All these parameters may be mapped with MRI. However, the integration of several MRI maps is difficult. This wealth of information is however difficult to interpret. Moreover, there are tight physiological links between these parameters. It should thus be possible to define clusters of pixels with similar physiological characteristics. In this study, multiparametric MRI data collected on tumor patient were analyzed with a model-based cluster approach.

Materials and Methods

Groups. Sixteen subjects (11 males/5 females) with untreated brain tumor were examined after written informed consent was obtained (approved by local IRB). Group was composed of 8 glioblastomas, 3 oligoastrocytomas, 2 oligodendrogliomas, 2 gliomatosis, 1 ganglioglioma.

Acquisition. The imaging protocol was carried out on a 3T TX Achieva MR scanner (Philips Healthcare®) using a whole-body RF transmit and 8-channel head receive coils. In addition to FLAIR and a pre and post-Gd T1w, three sequences were acquired with a FOV of 224x20x184mm: a 3D multi gradient echo (GE) sequence to obtain a T_2^* estimate; a multiple spin-echo experiment for T_2 mapping; a perfusion sequence with injection of a bolus of Gadolinium-DOTA (0.1mmol/kg, Guerbet, France) to map cerebral blood volume (CBV) cerebral blood flow (CBF) and mean transit time (MTT). The final spatial resolution was 2*2*4mm.

Data Analysis. As described in the literature, Perfusion maps were obtained pixelwise using a deconvolution approach (automated arterial input function detection) and StO_2 maps were obtained pixelwise from a combination of CBV and T_2^* where $1/T_2^* = 1/T_2 + 1/T_2'$ and using a hematocrit of 0.4 [2]. A map of Cerebral Metabolic Rate of oxygen ($CMRO_2$) was eventually computed using $CMRO_2 = CBF \times (1 - StO_2/100)$. Each pixel was thus characterized by T_2 , T_2^* , CBF, CBV, StO_2 and $CMRO_2$. Two regions of interest (lesion and controlateral) were manually drawn by an experimented neuroradiologist on the FLAIR image. Then, a model-based cluster analysis was performed on all the voxels within the two ROIs and from the 16 patients. Briefly, normal mixture modeling was performed using an Expectation-Maximization algorithm implemented in the R package mclust [3]. Model choice and the optimal number of clusters ($k=6$ clusters) were determined with the Bayesian information criterion [3].

Results

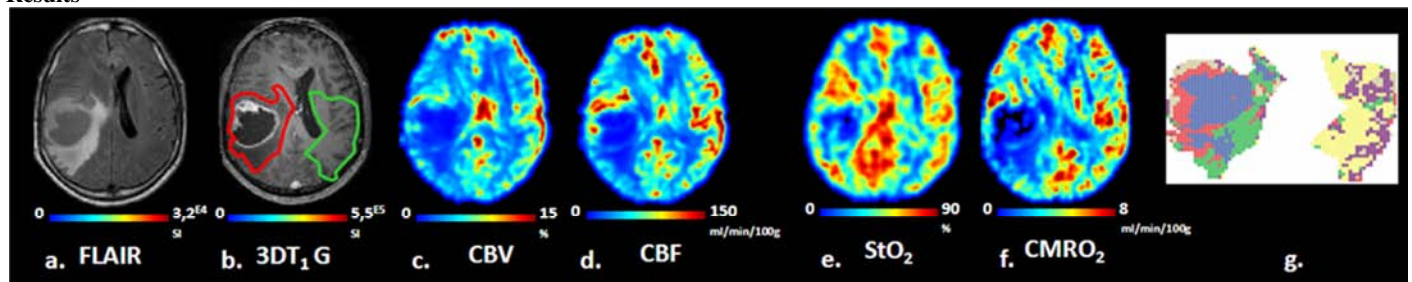


Figure 1. FLAIR (a), 3D T1 Gd (b). CBV (c), CBF (d), StO_2 (e) $CMRO_2$ maps (f) and model-based cluster analysis (g) from one patient with glioblastoma.

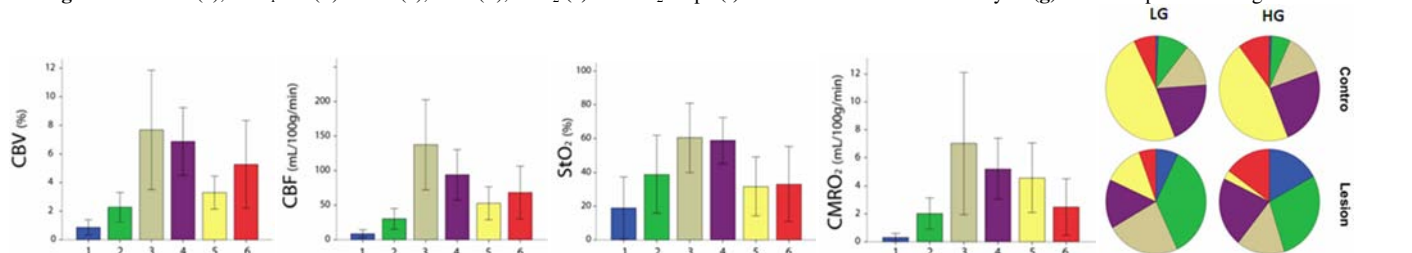


Figure 2. CBV, CBF, StO_2 and $CMRO_2$ in the 6 clusters numbered 1 to 6 (mean \pm SD across the patients) and representation of each cluster in the two ROIs for low and high grade tumor.

Fig. 1 shows representative parametric maps obtained from one patient. The model-based cluster analysis (**Fig.1g**) shows that white and gray matter are composed of the same clusters (#5 yellow, #4 magenta), which can thus be related to “healthy” voxels. Cluster #1 corresponds to necrotic tissue. Cluster #2 corresponds to edema. Cluster #6 corresponds to an area in which contrast agent extravasates. Cluster #3 is comparable to cluster #4 but exhibits a higher CBF. It is more represented in low grade tumors (**Fig 2**, pie graphs). The pie graphs further show that clusters #1 and #2 are mostly found in the lesion. Conversely, cluster #5 is mostly found in the controlateral ROI. However, some clusters (#3, #4 and #6) appear in both ROIs. Cluster #1 (necrosis) is more represented in the High grade than in the low grade while cluster #2 is more represented in the low grade than in the high grade.

Discussion / Conclusion

This study demonstrate the potential of using a model-based cluster analysis to integrate the information collected using multiparametric microvascular MRI in patient bearing a brain tumor. The clusterisation used in this study was based on 6 quantitative maps. Additional maps could be integrated such as permeability of apparent diffusion coefficient to refine the robustness of the clustering. Further studies should include a comparison between this type of clustering and results obtained by a pathologist. This cluster-based analysis of the tumor microvascular characteristic has a great potential to ease tumor diagnosis, prognosis, and treatment follow-up.

References

[1] Galban CJ et al. Clin Cancer Res 2011. [2] Christen T et al. NMR in biomed 2011. [3] Fraley and Raftery, J Am Stat Assoc, 2002.