

Non ECG-Triggered Self-Navigated 3D Radial Whole-Heart Cine MRI with High Spatial Resolution for Simultaneous Multi-Phase Coronary and Functional Imaging.

Simone Coppo^{1,2}, Davide Piccini^{3,4}, Gabriele Bonanno^{1,2}, Jerome Chaptinel^{1,2}, Gabriella Vincenti⁵, and Matthias Stuber^{1,2}

¹Center for Biomedical Imaging (CIBM), Lausanne, Switzerland, ²Radiology, University Hospital (CHUV) and University of Lausanne (UNIL), Lausanne, Switzerland,

³Advanced Clinical Imaging Technology, Siemens Healthcare IM BM PL, Lausanne, Switzerland, ⁴Radiology, University Hospital (CHUV) and University of Lausanne (UNIL)/ Center for Biomedical Imaging (CIBM), Lausanne, Switzerland, ⁵Division of Cardiology and Cardiac MR Center, University Hospital (CHUV), Lausanne, Switzerland

Target Audience: Basic researchers interested in cardiovascular and coronary imaging.

Purpose: In recent years, self-navigation has been demonstrated to significantly improve the time efficiency of whole-heart coronary magnetic resonance angiography (MRA) [1]. Despite this improvement, only a small percentage of time in the cardiac cycle is used for data collection, which makes the technique still very time inefficient. However, the amount of information collected per unit time, or duty cycle, may be significantly improved by continuously collecting data throughout the cardiac cycle. In theory, this enables multi-phase cine acquisitions and even 4D imaging [2-4]. For these reasons, we have implemented and tested a novel self-navigated free-breathing whole-heart 3D cine technique that has a high isotropic spatial resolution and that does not require electrocardiogram (ECG) triggering. We have tested the hypothesis that both coronary anatomy and ventricular function can simultaneously be assessed in vivo and in human subjects using this approach.

Methods: The protocol was approved by the local ethics committee and all healthy adult volunteers (n=7) provided written informed consent. Data were acquired on a 1.5 T MR system (MAGNETOM Aera, Siemens Healthcare, Erlangen, Germany) with 30 element of the posterior and anterior coils. A self-navigated 3D radial whole-heart balanced steady-state free precession (bSSFP) acquisition with spiral phyllotaxis trajectory [5] was performed continuously without ECG triggering during free breathing and a scan time of 14:17 min. However, the ECG trace was recorded during the scan. During the acquisition, 5749 segments composed of 22 radial profiles each were acquired, for a total of 126478 radial k-space profiles. Sequence parameters included: TR/TE=3.1/1.56ms, FOV=(220mm)³, acquired voxel size=(1.15mm)³, matrix size=192³, radiofrequency excitation angle=90°. Each data segment was preceded by CHESS fat saturation. The continuously acquired k-space profiles were then regrouped in bins of 100ms duration (can freely be chosen by the operator) as a function of their relative position within the R-R interval (Fig.1.A). Overlapping bins were extracted every 20ms with 80% view sharing until the entire R-R interval was covered. Self-navigation [6] was then applied to compensate for respiratory motion and one respiratory motion-corrected 3D cardiac cine phase was then reconstructed for each bin individually (Fig.1.B). In the thus-obtained 3D cine dataset, the periods of coronary quiescence at end-systole and mid-diastole were identified. From these time intervals, two 3D volumes optimized for coronary visualization were reconstructed, since the reconstruction allows to freely select the acquisition window size and position in the cardiac cycle (Fig.1.C). From these end-systolic and mid-diastolic datasets, the left ventricular end-systolic (ESV) and end-diastolic (EDV) volumes were extracted through manual segmentation in an axial view and with a custom-written Matlab (The Mathworks, Natick, MA, USA) algorithm. The ejection fraction (EF) was then computed as: $EF=(EDV-ESV)/EDV$. For gold standard comparison, a stack of bSSFP 2D cine images covering the entire left ventricle was acquired in a short axis orientation using breath holding (FOV=300x171mm, voxel size=1.17x1.17x8mm). From these short-axis images, volumes were calculated by applying Simpson's rule and ESV, EDV and EF were then measured using Argus VF software (Siemens Medical Systems). These results were subsequently compared to those obtained from the 3D cine analysis. The two analyses were blinded, and the results were compared with a paired Student's t-test with a p-value <0.05 considered statistically significant. For baseline comparison of the coronary anatomy, a conventional, ECG-triggered mid-diastolic 3D self-navigated whole-heart scan with T₂ preparation [7] was also acquired.

Results and Discussions: The 3D cine datasets were successfully acquired in all volunteers. This technique enables the dynamic assessment of the whole heart in 3D with an isotropic spatial resolution of 1.15mm³, thus allowing for retrospective and flexible reformatting at any user-specified anatomical level of the heart. A high correlation (correlation statistics not shown) was found between the EDV obtained from the 3D cine and the standard 2D cine approach (mean EDV_{3D}=143±116ml, mean EDV_{2D}=146±139ml, p=0.7), while the ESV was slightly overestimated by the 3D cine technique (mean ESV_{3D}=66±52ml, mean ESV_{2D}=53±50ml, p=0.004). This also led to an underestimation of the EF (mean EF_{3D}=55±48%, mean EF_{2D}=65±65%, p<0.001). This difference may be attributed in part to the larger voxel size and partial volume effect of the 2D technique. However, bias originating from the 3D approach cannot be excluded at this stage. Contiguous and long coronary segments were successfully visualized in all subjects. Note the very distal segments of the right coronary artery (Fig.1.C) that are better visualized in diastole while its proximal and mid counterparts are better delineated in systole. Image quality was very similar to the conventional self-navigated scan (Fig.1.C) albeit with some penalty in SNR.

Conclusions: A novel, non-ECG triggered and self-navigated 3D radial whole-heart cine sequence was developed and implemented. We successfully tested the hypothesis that both coronary anatomy and ventricular function can be assessed simultaneously in vivo and in humans. The ability to freely and retrospectively select both acquisition window width and position offers the unprecedented opportunity to best visualize each coronary segment at its individual time point of relative quiescence.

References: 1.Stehning et al. MRM.2005;54(2):476; 2. Lai et al. MRM. 2008;59:1378; 3.Spincemaille et al. MRI.2011;29(6):861; 4.Wu HH, et al. MRM.2013;69(4):1083; 5.Piccini et al. MRM. 2011 66(4):1049; 6.Piccini et al. MRM. 2012, 68(2) :571; 7.Piccini et al. Radiology, 2013, in press;

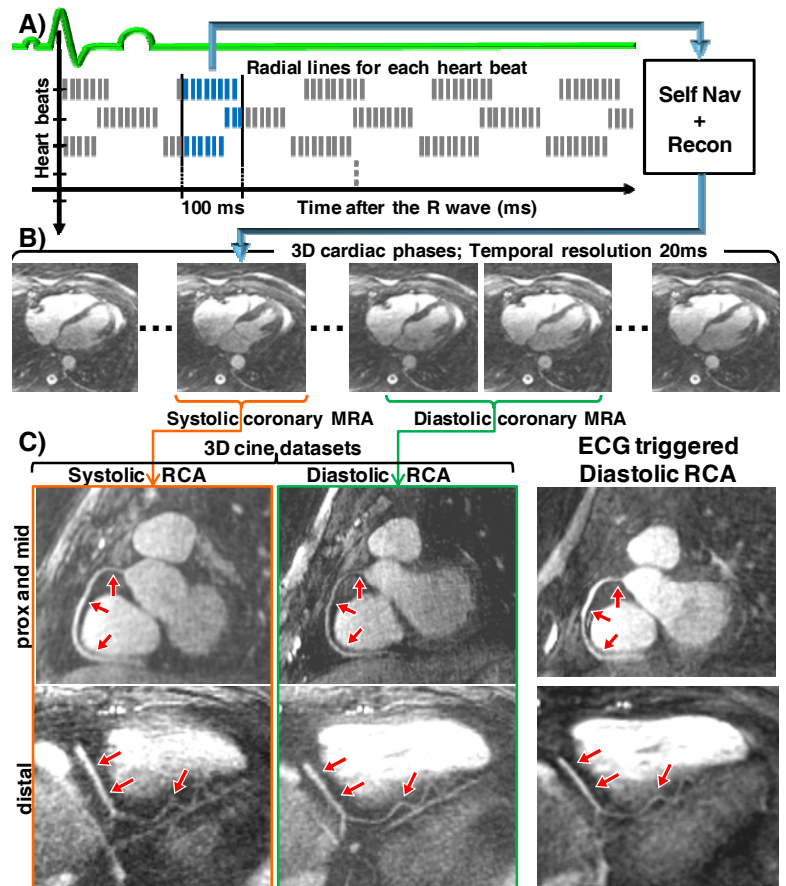


Figure 1: A) Binning of the lines as a function of their time after the R-wave to reconstruct a cardiac phase. B) Selection of the low coronary motion periods for the coronary MRA reconstruction. C) Reformat of the RCA of one volunteer from the optimized systolic (left) and diastolic (center) volumes of the 3D cine dataset compared to the reformat from the 3D ECG triggered mid-diastolic acquisition (right). Proximal and middle reformat on top and distal reformat at the bottom.