

Oxygen-enhanced T1-mapping MRI of the lung in patients with chronic lung-allograft dysfunction

Jens Vogel-Claussen^{*1}, Julius Renne^{*1}, Peer Lauermann¹, Jan Hinrichs¹, Christian Schönfeld¹, Sajoscha Sorrentino¹, Marcel Gutberlet¹, Peter Jakob², Axel Haverich¹, Gregor Warnecke¹, Tobias Welte¹, Frank K Wacker¹, and Jens Gottlieb¹

¹Hannover Medical School, Hannover, Niedersachsen, Germany, ²University of Würzburg, Würzburg, Germany

Target audience – MDs and PhDs interested in lung MRI and lung transplantation.

Purpose – To evaluate oxygen-enhanced T1 mapping MRI of the lungs for the detection of chronic lung allograft dysfunction in long-term patients following double-lung transplantation.

Methods – This study in a single high-volume center followed the declaration of Helsinki principles and was approved by the local ethics committee. 50 patients >12 months after double-lung transplantation were included in this study. Each patient underwent a single lung MRI examination as part of his /her routine clinical visit to the lung transplant outpatient clinic. Bronchiolitis obliterans syndrome (BOS)/ chronic allograft dysfunction was diagnosed as a decrease in forced expiratory volume in 1 second (FEV1) compared to best FEV1 after transplant without any known causes as previously described (1). An inversion recovery snapshot fast low-angle shot (FLASH) sequence at 1.5T with an 8 channel torso phased array coil was used (2): TE 0.8ms, TR 3.0ms, flip angle 8°, 32 inversion times within a timeframe of 200ms - 6400ms, acquisition matrix 128 x 64, field of view 50cm x 50cm, slice thickness 15 mm, gap 7.5mm. Coronal slices covering both lungs were acquired. Images were obtained after breathing room air and again at the same slice position while breathing 100% oxygen. Oxygen was administered using a full covering air cushion face mask with a filter, a 2.6 liter reservoir and a flow rate of 15 l/min O₂. Images acquired breathing oxygen were registered on the room air images using a phase-sensitive non-rigid registration algorithm (Advanced Normalization Tools, 3). Afterwards T1 maps were calculated using non-linear image registration and a self-developed MATLAB script (MATLAB 2012a, Mathworks, Ismaning, Germany). Lungs were segmented on the room air T1 maps and then transferred onto the corresponding co-registered oxygen T1 maps. As functional parameter the difference between T1 times breathing room air and 100 % oxygen ($\Delta T1 = T1_{21\%O_2} - T1_{100\%O_2}$) was calculated.

Results – The mean T1 relaxation times of the total lung did not differ between the three groups (1: BOS 0, 2: BOS 0p and 3: BOS1-3) for both the room air (p=0.28, BOS 0: 1183 [1152;1269] ms, BOS0p: 1161 [1073;1200] ms, BOS 1-3: 1143 [1132;1205] ms) images as well as the images obtained breathing oxygen (p=0.79, BOS 0: 1058 [1022;1119] ms, BOS0p: 1063 [1019;1098] ms, BOS 1-3: 1048 [1025;1078] ms). The coefficient of variation of both lungs differed significantly for the room air T1 relaxation times (p=0.01, Figure 1A) as well as for the T1 maps acquired breathing oxygen (p=0.0005, Figure 1B) between the three groups. The coefficient of variation increased for BOS 0p (room air: p=0.03, oxygen: p=0.14) as well as for BOS1-3 compared to BOS0 (room air: p=0.003, oxygen: p=0.0008). There was a significant (p=0.03) difference between the three groups for the difference of T1 relaxation times ($\Delta T1 = T1_{room_air} - T1_{100\%O_2}$) (Figure 1C).

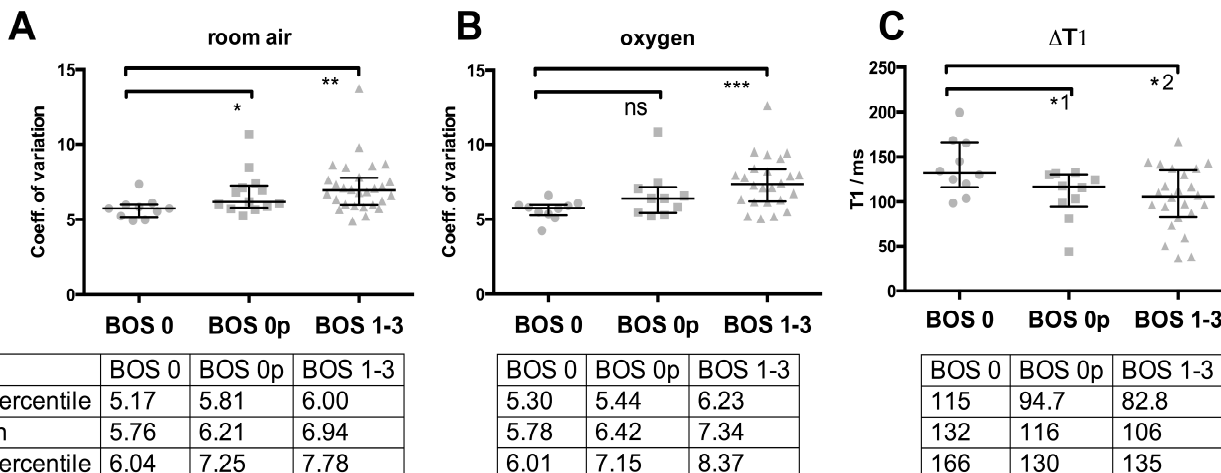


Figure 1: Coefficient of variation for both lungs A) breathing room air (*p=0.03, **p=0.003) and B) oxygen (ns p=0.14, ***p=0.0008). C) Difference between T1 times ($\Delta T1$) acquired under room air and under oxygen (*1 p=0.04, *2 p=0.01).

Discussion – In this study oxygen-enhanced T1 mapping MRI shows increased heterogeneity of T1 relaxation times within the lung parenchyma for patients with chronic lung transplant rejection (BOS 1-3) as well as patients with BOS 0p status compared to patients without BOS (BOS 0). Furthermore, in patients with BOS and BOS 0p $\Delta T1$ is reduced in the lung parenchyma, compared to patients without BOS.

Conclusion – Oxygen-enhanced T1 mapping MRI of the lung is capable of detecting pulmonary alterations occurring in patients with chronic lung rejection after transplantation. The coefficient of variation and $\Delta T1$ between room air and 100% oxygen may serve as novel biomarkers for early BOS.

References – 1. Estenne M et al. J. Heart Lung Transplant. 2002;21(3):297–310. 2. Jakob PM, et al. J Magn Reson Imaging. 2001;14(6):795–9. 3. Xue H, et al. Magn Reson Med 2012;67(6):1644:1655.

*Jens Vogel-Claussen and Julius Renne contributed equally to this work.