

MRI as a complementary tool in motion management for patients undergoing radiation therapy for thoracic tumors

Xiutao Shi¹, Tejan Diwanji¹, Jolinta Lin¹, Warren D. D'Souza¹, and Nilesch N. Mistry¹

¹Department of Radiation Oncology, University of Maryland School of Medicine, Baltimore, MD, United States

TARGET AUDIENCE: To assist radiation oncologists and medical physicists in determining treatment margins to fully estimate tumor motion in the thorax.

PURPOSE: Conventionally, margins for mobile tumors in the thorax are derived from the 4DCT treatment planning images. These images are acquired in ~1 min to avoid excessive radiation to patients. In contrast, the duration of the radiation treatment is significantly longer (>10 min). The underlying assumption in using a single 4DCT scan prior to the 1st treatment session to estimate the range of tumor motion is that the ~1 min scan sufficiently captures the range of respiratory motion needed to cover the entire duration of treatment. With the help of an automated tumor tracking technique using template matching and dynamic MRI images captured in between several treatment sessions, the goal of this study was to test the appropriateness of the margins determined with 4DCT images by comparing the tumor movement in cine-MRI images to that in 4DCT images.

METHODS: Eleven patients with non-small cell lung cancer (NSCLC) were recruited in a prospective study. Cine-MRI was performed at 3 different sessions: before treatment, 1-2 weeks into treatment, and 4-5 weeks into treatment. Multi-slice 2D-TrueFISP (fast imaging with steady-state precession) cine-images were obtained in the sagittal plane with the following parameters: TE/TR/Flip-angle/Matrix-size/Slice-number of 1.29ms/2.57ms/60°/176x256/5. In-plane spatial resolution was ~1.95 mm, and slice thickness ranged from 9-16 mm. Dynamic imaging was carried out for ~8 min for each session, acquiring ~200 image frames with 5 slices each. Typically, the central slice that contained the tumor was selected from each dataset to create a series of ~200 frames with a temporal resolution of ~2.5 s. A single 4DCT image dataset was acquired for each patient prior to the start of treatment, and was used to estimate tumor motion. The respiratory cycle was captured at 10 different phases using the Varian real-time position management (RPM) system. The sagittal slice corresponding to the one used in cine-MRI images was visually selected for each of the 10 phases of the 4DCT volumes by a radiation oncologist (Fig. 1).

On the 4DCT images of each patient, the margin was calculated as one half of the distance between the two extreme tumor positions in the anterior-posterior (AP) and superior-inferior (SI) directions, respectively. Template matching was applied to both the cine-MRI and 4DCT images to estimate the range of tumor motion. For each image dataset, a minimum enclosing rectangular box that contained the tumor was drawn on the first frame by a radiation oncologist to serve as the template. On all subsequent frames, this template was moved around in the target image to calculate the normalized cross-correlation between the template and the target. The position with the best correlation determined the position of the tumor on that frame (Fig. 1). The percentage of time when the tumor movement was larger than the determined margin (from 4DCT) was quantified in the AP and SI directions, respectively. Further processing involved estimating the percentage of time spent outside the margins by increasing the margins by 2 or 4 mm in each direction.

RESULTS: The percentage of the time when the tumor moved out of the margins determined with 4DCT images was showed as the total height of the columns in Fig. 2. This total height was divided into three portions – within 0-2 mm additional margin, within 2-4 mm additional margin, and outside the 4 mm additional margin. For 7 out of the 11 patients analyzed, the tumor moved out of the margin determined with 4DCT in one or more imaging sessions and spent more than 10% up to 53.5% of the time outside the margins. If an additional 2 mm margin was added on top of the margin determined with 4DCT, the percentage of time when the tumors spent outside the margins was reduced to an average of 4.9% (0-31.5%) for these patients. A total of 4 mm additional margin further reduced the average to 1.1% (0-9.5%).

DISCUSSION AND CONCLUSION: Proper selection of the internal margin for mobile tumors in the chest is crucial to limit the dose to surrounding healthy tissues, and going forward can be very critical especially with the desire to escalate the radiotherapeutic dose. In this study, the appropriateness of the margins determined with conventional 4DCT images was investigated by comparing the range of tumor motion observed over ~8 min using cine-MRI images to that in 4DCT images. Results from this study show that tumors in 7 out of the 11 patients recruited spent a significant portion of the time outside the margins traditionally considered enough to estimate the motion. This suggests that margins determined with the 1-min 4DCT images are often not enough for most patients.

The margins determined with 4DCT were sufficient for only about 1/3 of patients. However, adding about a 2 mm additional margin improved the results for most patients. This result seems pronounced in the AP direction in the cases presented in this study. Based on these results one might consider using individualized and heterogeneous margins determined using a longer duration scan to estimate the range of motion. However, that would again be a snapshot of what the range of motion would be during the imaging session. In conclusion, the inclusion of cine-MRI images showed that margins determined with conventional 4DCT images are not enough for most patients. This study suggests the potential complementary role of MRI in determining the margins for mobile tumors due to its non-ionizing nature.

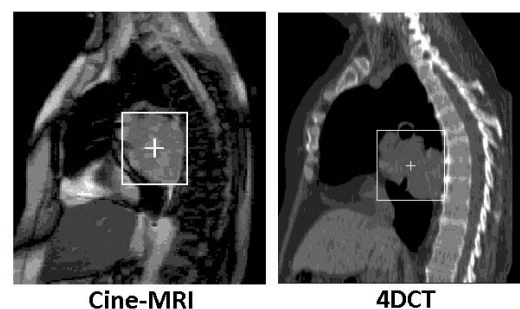


Figure 1: In 4DCT images (right), the sagittal slice that corresponded to the one used in cine-MRI images (left) was visually identified by a radiation oncologist. The boxes and crosshairs indicate the size and position of the tumor.

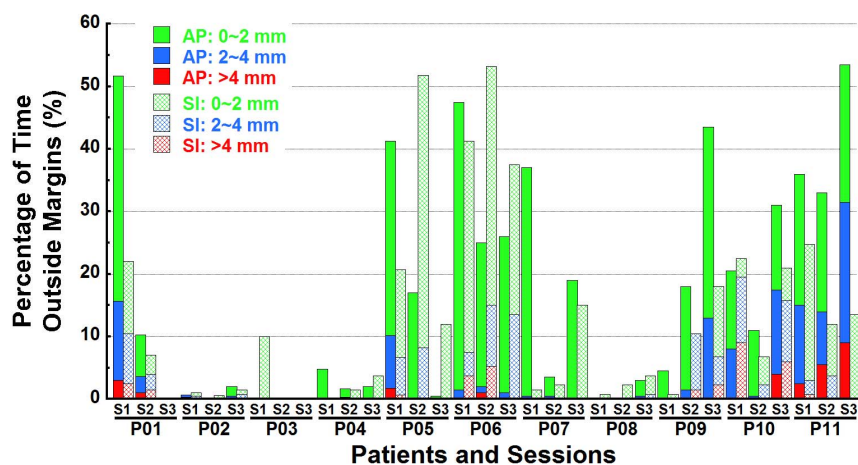


Figure 2: The percentage of time tumors moving out of margins determined with 4DCT images was showed for all patients and all imaging sessions in the AP and SI directions, respectively.