

Identification of Arterio-Venous Shunts by Vessel Architectural Imaging Reveals Mechanisms of Vascular Normalization during Anti-Angiogenic Therapy

Guro K. Rognsvag¹, Atle Bjørnerud^{1,2}, A. Gregory Sørensen^{3,4}, Patrick Y. Wen⁵, Tracy T. Batchelor^{6,7}, Rakesh K. Jain⁶, and Kyrre E. Emblem^{1,3}

¹The Intervention Centre, Oslo University Hospital, Oslo, Oslo, Norway, ²Dept of Physics, University of Oslo, Oslo, Norway, ³Department of Radiology and Athinoula A. Martinos Center for Biomedical Imaging, Massachusetts General Hospital and Harvard Medical School, Boston, MA, United States, ⁴Siemens Healthcare, Malvern, PA, United States, ⁵Center for Neuro-Oncology, Dana-Farber/Brigham and Women's Cancer Center and Harvard Medical School, Boston, MA, United States, ⁶Department of Radiation Oncology, Massachusetts General Hospital and Harvard Medical School, Boston, MA, United States, ⁷Department of Neurology, Massachusetts General Hospital and Harvard Medical School, Boston, MA, United States

TARGET AUDIENCE: Clinicians, biologists and researchers involved in cancer imaging studies and clinical trials using anti-angiogenic therapy.

PURPOSE: The microvasculature of tumors is abnormal and tortuous with arterio-venous shunts. Shunts are short high-flow vascular pathways that cause parts of the blood flow to bypass capillary regions downstream as well as other, longer pathways [1]. Functional shunts with limited surface area impair delivery of oxygen to the tissue and increase resistance to therapy [2,3]. Vessel architectural imaging (VAI) has recently been introduced as a new paradigm for *in vivo* assessment of cancer vasculature [4] (Fig. 1A-B). We hypothesize that VAI can identify arterio-venous shunts in patients with recurrent glioblastomas and help reveal mechanisms of response to anti-angiogenic therapy.

METHODS: First, to understand the VAI response to arterio-venous shunts, we used Monte Carlo simulations of intravascular magnetic susceptibility perturbations as previously described [4,5]. A realistic branching of vessels was obtained by using a vessel tree model [6], where the vessel generations are self-similar and follow Murray's law (Fig. 1C). Capillaries were gradually removed from the vessel tree and the arterial and venous oxygenation saturation levels (SO₂) varied from hyperoxic to anoxic scenarios to mimic impaired oxygen delivery [4]. A parameter coined as the *shunt index* was introduced, defined as the slope of the vessel vortex curve divided by the length of the vortex curve (Fig. 1B). The slope and length of the vortex curve have previously been reported to yield distinct differences in simulations of normal tissue compared to shunting vessels [4]. Second, we evaluated MRI data of patients with recurrent glioblastomas enrolled in a Phase II clinical trial of the anti-angiogenic drug cediranib (clinicaltrials.gov, NCT00305656). Gadolinium-based gradient-echo and spin-echo dynamic susceptibility contrast MRI was performed at 3T (Siemens) prior to therapy onset (days -5 and -1) and repeated at days 1, 28, 56 and 112 as previously reported [7]. Shunt indexes of patients identified as responders to cediranib by increased perfusion [8] were compared to non-responders with stable or reduced perfusion using Kruskal-Wallis tests and adjusted for variations in blood volume.

RESULTS: Compared to normal tissue, our simulations show that the slope of the vortex curves increase whereas the vortex lengths decrease in shunting tissue. The resulting shunt index for normal tissue is reduced with increasing volume fractions (by distension), whereas the shunt index is stable or increasing in shunts (Fig. 1D). Example pre- and post-therapy shunt index maps overlaid on contrast-enhanced MRIs are shown in Figure 1E. Patients identified as responders by vascular normalization had reduced shunt index values at days 1 and 28 ($P < 0.05$) compared to non-responders (Fig. 1F). Responding patients lived approximately 6 months longer than non-responding patients (median overall survival 348 days vs 169 days; $P < 0.001$, [8]).

DISCUSSION: By VAI, our simulations show higher shunt indexes in shunting tissue compared to normal tissue. Abnormal shunt indexes were also observed in patients with recurrent glioblastomas before anti-angiogenic therapy. Patients with vascular normalization from increase in perfusion had reduced vessel shunting in the tumor during the first month of anti-angiogenic therapy by cediranib. Our findings support the hypothesis that restoring mechanisms that counteract shunting underlies the successful normalization of tumor vasculature by anti-angiogenic therapy [1].

CONCLUSION: We show that VAI identifies arterio-venous shunts and help reveal mechanism of normalization during anti-angiogenic therapy.

REFERENCES:

- [1] Pries AR et al, *Nat Rev Cancer* 2010;10(8):587–593,
- [2] Bergers G et al, *Nature Rev Cancer* 2008;8(8):592–603,
- [3] Ellis CG et al, *AJP Heart Circ Physiol* 2002;282(1):156–64,
- [4] Emblem KE et al, *Nat Med.* 2013;19(9):1178–83,
- [5] Boxerman JL et al, *Magn Reson Med* 1995;34:555–566,
- [6] Xu C et al, *Magn Reson Med* 2013;69:981–991,
- [7] Batchelor TT et al, *Cancer Cell* 2007;11(1):83–95,
- [8] Sørensen AG et al, *Cancer Res* 2012;72(2):402–7

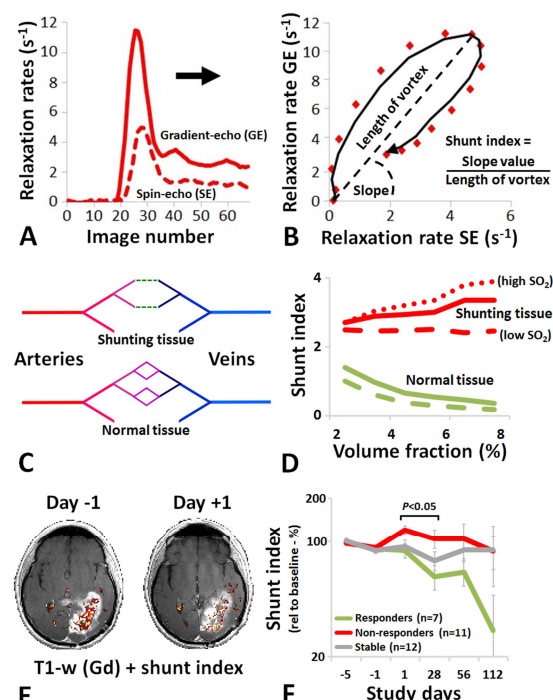


Figure 1: (A) VAI compares simultaneously acquired gradient-echo (GE) and spin-echo (SE) DSC-MRI curves. (B) In a point-by-point scatterplot, the GE and SE data may lag or lead each other attributed to different sensitivity to deoxygenated blood and this is used to estimate the shunt index. (C) Simulated vessel tree models with (normal) and without (shunt) capillaries. (D) Resulting theoretical shunt indexes to various normal- and shunting scenarios. (E) Shunt index maps on anatomical MRI showing high shunt indexes at baseline (day -1) and reduced shunting during anti-angiogenic therapy (day +1). (F) Patients with vascular normalization have reduced shunts indexes compared to non-responding patients.

Example pre- and post-therapy shunt index maps overlaid on contrast-enhanced MRIs are shown in Figure 1E. Patients identified as responders by vascular normalization had reduced shunt index values at days 1 and 28 ($P < 0.05$) compared to non-responders (Fig. 1F). Responding patients lived approximately 6 months longer than non-responding patients (median overall survival 348 days vs 169 days; $P < 0.001$, [8]).

By VAI, our simulations show higher shunt indexes in shunting tissue compared to normal tissue. Abnormal shunt indexes were also observed in patients with recurrent glioblastomas before anti-angiogenic therapy. Patients with vascular normalization from increase in perfusion had reduced vessel shunting in the tumor during the first month of anti-angiogenic therapy by cediranib. Our findings support the hypothesis that restoring mechanisms that counteract shunting underlies the successful normalization of tumor vasculature by anti-angiogenic therapy [1].

We show that VAI identifies arterio-venous shunts and help reveal mechanism of normalization during anti-angiogenic therapy.