

Perforant pathway tracking in human temporal lobe ex vivo tissue.

Luis Manuel Colon-Perez¹, Mansi Parekh², Michelle Couret³, Rosemary Klassen³, Michael King⁴, Paul Carney⁵, and Thomas Mareci¹

¹Biochemistry and Molecular Biology, University of Florida, Gainesville, FL, United States, ²Radiology, Stanford University, Stanford, CA, United States, ³University of Florida, FL, United States, ⁴Pharmacology and Therapeutics, University of Florida, FL, United States, ⁵Pediatrics, University of Florida, FL, United States

Introduction: White matter (WM) structures of the brain can be reconstructed by following the primary eigenvector of a calculated diffusion tensor¹. This approach works well for large homogenous white matter tracts (e.g. corpus callosum and cingulum), but it's not as successful for smaller and more complicated paths, like the perforant pathway. More advanced modeling of the diffusion displacement might improve tracking for smaller fiber bundles by resolving crossing and kissing fibers. The perforant pathway is a bundle of axons that provide direct connections from the entorhinal cortex (EC) to all subfields of the hippocampus (HC). This pathway is a complicated structure that is difficult to visualize in clinical data. In order to study the pathway, we acquired high spatial resolution diffusion weighted images of an excised human temporal lobe, which reduced volume averaging to determine if this small fiber pathway could be resolved. This study's method to visualizing the perforant pathway could eventually lead to a more complete description of this axonal structure.

Methods: The University of Florida Institutional Review Board approved this study. An excised fresh human right temporal lobe was scanned with a diffusion-weighted imaging (DWI) spin echo sequence at 17.6 T with a 220 microns isotropic resolution using TR/TE= 4000/28 ms, $\Delta/\delta = 17.5/3.5$ ms, 64 directions at $b=2225$ s/mm² and 6 directions at $b=100$ s/mm². The diffusion data was interpolated to 110 microns isotropic. In order to determine the diffusion displacement probability, a mixture of Wishart (MOW) distributions model² was employed to resolve multiple fibers orientations in a single voxel. Each fiber orientation was used to perform deterministic tractography, employing the FACT algorithm, in the entire temporal lobe with a 125 seeds per voxel. Probabilistic tractography was also performed from regions of interest in the HC (Figure 1F) using FSL's probtrackx algorithm with 5000 seeds per voxel. The temporal lobe tissue was preserved in paraffin blocks and segmented in 7 microns thick slices. Then, the slices were stained for neurofilaments (Biogenex, Fremont, CA, MU073-UC). Finally, the stained slices were imaged with an optical microscope at a 1 x 1 micron resolution.

Results: The temporal lobe FA map shows detailed structures within the hippocampus (e.g. dentate gyrus and alveus). The temporal lobe density streamline map (Fig.1G) shows a pattern of streamlines that resemble the trajectory of the perforant pathway; arising in the entorhinal cortex, perforating the subiculum, and traveling to the dentate gyrus and CA3/1. Histology has been used to validate DTI results³, but no tractography validation of small tracks, such as the perforant pathway, has been performed. With the aid of histological sections, the validity of figures 1G-J was determined with Figure 1E. The obtained fiber structures can be confirmed in the multiple histological sections. With this work we have successfully observed the three dimensional projection of the perforant pathway fibers as streamlines derived from tractography by using high-resolution diffusion weighted imaging.

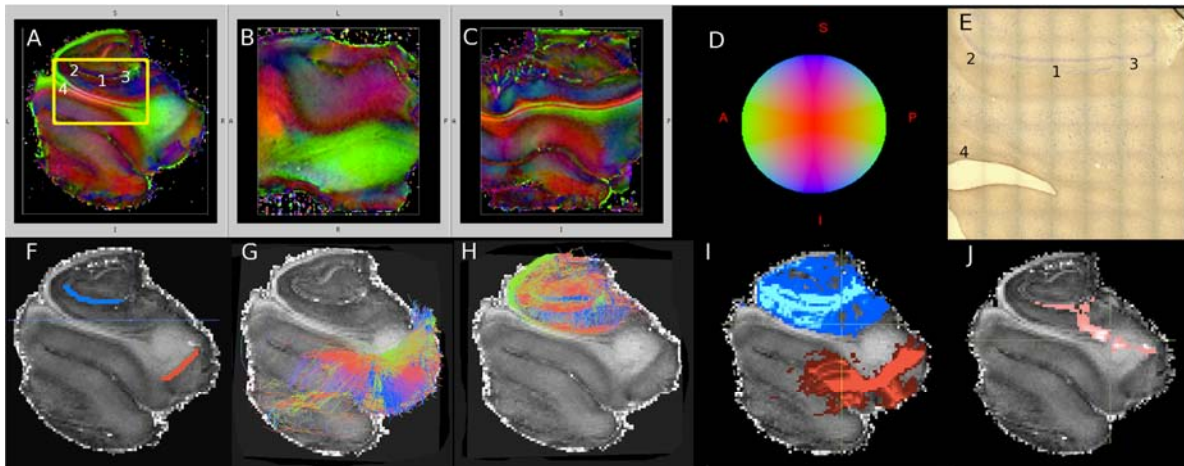


Figure 1. Temporal lobe images. (A-C) Fractional anisotropy (FA) maps of the temporal lobe. (D) Color scheme representing the direction of the primary eigenvector of the diffusion tensor. Legend for the temporal lobe FA map numbers: (1) CA1, (2) CA3, (3) dentate gyrus and (4) alveus (green structure surrounding the hippocampus). (E) Histology slice of the yellow box in Figure 1-A. (F) Regions of interest (ROI); blue ROI located at the CA1, CA2 and dentate gyrus of the hippocampus (HC) and red ROI located at the white and grey matter interface of the entorhinal cortex (EC). (G) Deterministic streamlines; 3D projections of streamlines passing through the EC (H) Deterministic streamlines; 3D projections of streamlines passing through the HC (I) Deterministic tractography; displaying a map of the number of streamlines that are passing through the HC ROI (blue region) and the EC ROI (red region) of Figure 1G-H. (J) Probabilistic tractography; a map of the number of streamlines originating from the HC ROI and passing through the EC ROI (pink region). Intensity of color in figures F-H correspond the number of streamlines passing through the voxels; bright color high number of streamlines and dark color low number of streamlines.

Acknowledgements: This work was supported by NIH grant R01NS063360, the State of Florida Brain and Spinal Cord Injury Research Trust Fund, and the B.J. and Eve Wilder Endowment Fund. The data was acquired on the Advanced Magnetic Resonance Imaging & Spectroscopy Facility at the McKnight Brain Institute of the University of Florida.

References, 1. Mori, S., Crain, B. J., Chacko, V. P. & van Zijl, P. C. Three-dimensional tracking of axonal projections in the brain by magnetic resonance imaging. *Annals of neurology* **45**, 265-9 (1999). 2. Jian, B., Vemuri, B. C., Ozarslan, E., Carney, P. R. & Mareci, T. H. A novel tensor distribution model for the diffusion-weighted MR signal. *NeuroImage* **37**, 164-76 (2007). 3. Budde, M. D. & Frank, J. a. Examining brain microstructure using structure tensor analysis of histological sections. *NeuroImage* **63**, 1-10 (2012).