

T2-Based Temperature Monitoring in Abdominal Fat during HIFU Treatment of Patients with Uterine Fibroids

Eugene Ozhinsky¹, Maureen Kohi¹, and Viola Rieke¹

¹Department of Radiology and Biomedical Imaging, University of California San Francisco, San Francisco, CA, United States

Target Audience: Researchers and clinicians interested in MRgHIFU.

Purpose: High intensity focused ultrasound (HIFU) is a non-invasive technique that ablates tissue using an external transducer by focusing the ultrasound beam from outside the patient into a small focal spot and raising its temperature beyond the lethal level. One of the most common applications of HIFU is ablation of uterine fibroids (UF). Near-field heating is a serious problem in UF treatments that may cause burns and necrosis of healthy tissue. Proton Resonance Frequency (PRF) shift thermometry is commonly used to monitor the heating during treatment. While effective in water-based tissues PRF thermometry cannot detect temperature change in abdominal fat. Previously, Baron et al. [1] described the use of T2 mapping to measure near-field heating and demonstrated its application in a Philips HIFU system. The goal of this study was to investigate near-field heating in patients treated with the InSightec fibroid system. Accurate measurement of near-field heating in adipose tissue could lead to shorter treatments by eliminating unnecessary cooling time between sonications while preventing injury in healthy tissues.

Methods: Fat temperature mapping was performed during two UF treatments using the ExAblate 2100 system (InSightec, Israel) with sonication energy up to 5000 J and duration of 20 s per sonication (86 and 98 sonications total). T2-maps of abdominal fat were acquired between sonications (14 and 13 images per patient, single coronal oblique slice (fig. 1), double echo Fast Spin Echo, water suppression, TR=1500ms, TE=35/181 ms, 15 sec acquisition time). Maps of temperature change were generated from Gaussian-filtered T2 maps, assuming a T2 change of 5.17 ms per °C [1].

Results: Fat temperature mapping has been performed during treatment of two patients with uterine fibroids. We observed a measurable change in T2 of fat tissue in the path of the ultrasound beam (fig. 1). The areas of the increased temperature after clusters of sonications matched the intersection of the US beam with the slice (fig. 2a). Fig. 2b shows the total change in temperature for the same time points. We observed temperature increase up to 18°C and sustained heating of more than 10°C for the duration of the treatment (fig. 3).

Discussion: Our preliminary results demonstrate the feasibility and importance of monitoring near-field heating in fatty tissues using T2 mapping. During treatment with the ExAblate system, near-field heating can reach high temperatures and cumulative thermal dose that may cause necrosis of adipose tissues [2,3]. The limitations of the current study include relying on previously reported calibration data [1] and lack of absolute temperature measurement. The baseline temperature of the subcutaneous fat may be significantly lower than the core body temperature due to limited blood perfusion and cooling from the transducer oil bath (cooled to 14°C). More frequent measurements will allow to better quantify the cumulative thermal dose and the rate of cooling after the sonication.

References and Acknowledgements: [1] Baron P. et al, Proc 21st ISMRM, 2013: 230; [2] Dewey, W. C., Int. J. of Hyperthermia, 1994; [3] Diederich, C. J., Int. J. of Hyperthermia, 2005; This work was supported by NIH Grants R00HL097030, and research support by GE and InSightec.

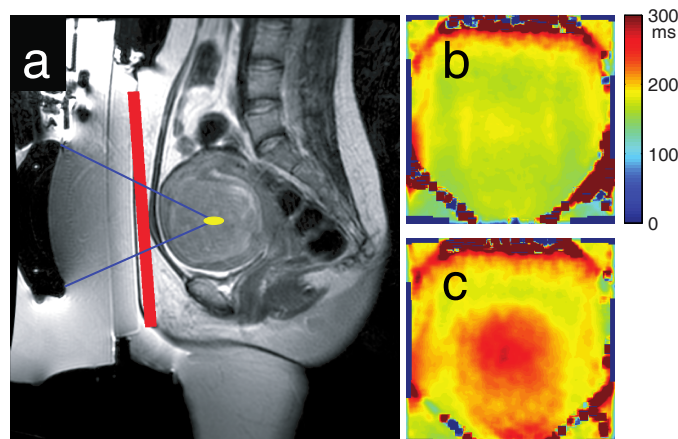


Fig. 1. (a) placement of the T2 mapping slice; (b) baseline fat T2 map; (c) T2 map during the treatment

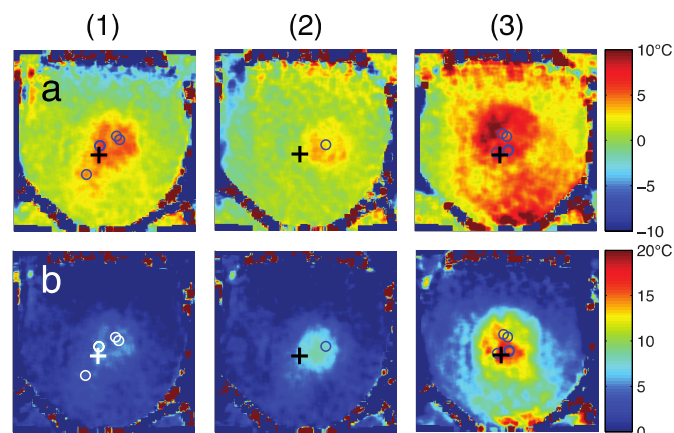


Fig. 2. (a) temperature change between subsequent measurements and (b) from baseline. Intersections of the beam axes and the slice are shown as circles, location of the measurement in fig. 3 as "+"

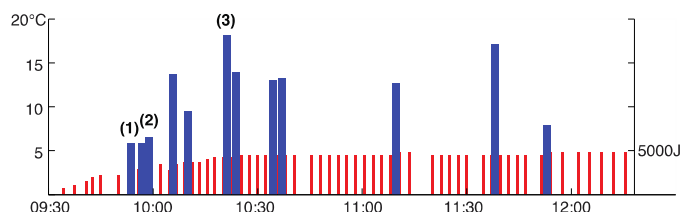


Fig. 3. Measured temperature change from baseline (blue bars) for the location marked with a cross in fig. 2 and energy of sonications (red bars) over the course of the treatment.