

## Hip T1rho and T2 relaxation times in individuals with and without cartilage lesions

Cory Wyatt<sup>1</sup>, Deepak Kumar<sup>1</sup>, Karupphasamy Subburaj<sup>2</sup>, Divya Narayanan<sup>3</sup>, Sonia Lee<sup>1</sup>, Lorenzo Nardo<sup>1</sup>, Thomas Link<sup>1</sup>, Thomas Vail<sup>4</sup>, Richard Souza<sup>1</sup>, and Sharmila Majumdar<sup>1</sup>

<sup>1</sup>Radiology and Biomedical Imaging, University of California San Francisco, San Francisco, CALIFORNIA, United States, <sup>2</sup>Radiology and Biomedical Imaging, University of California San Francisco, San Francisco, California, United States, <sup>3</sup>Bioengineering, University of California Berkeley, Berkeley, California, United States, <sup>4</sup>Orthopaedic Surgery, University of California San Francisco, San Francisco, CALIFORNIA, United States

**Introduction:** Acetabular cartilage defects, but not femoral cartilage defects or radiographic hip osteoarthritis (OA), have recently been shown to be associated with greater self-reported pain and disability in individuals with mild-moderate hip OA [1]. MR imaging using T1ρ and T2 relaxation times allows quantitative assessment of cartilage degeneration [2-4] as these measures are sensitive to changes in cartilage hydration, collagen integrity, and proteoglycan distribution. The purpose of this study was to compare *in vivo* hip cartilage T1ρ and T2 relaxation times in individuals with and without femoral and acetabular cartilage lesions.

**Methods:** Data from the left or right hip of 96 subjects [44 females, 52 males, mean age of 44.6±13.5 years (23-72), mean BMI of 23.7±3.0 kg/m<sup>2</sup> (16.5-31.0)] were scanned on a 3 Tesla MR scanner (MR750, GE Healthcare, Waukesha, WI). Subjects included 22 healthy controls, 60 with mild-moderate hip OA (radiographic Kellgren Lawrence between 1-3), and 14 with femoroacetabular impingement (FAI). Consent was obtained for each subject under an IRB approved protocol. Scanning was performed with an 8-channel phased array cardiac coil positioned near the study hip. Subjects were scanned with 2D T2-weighted FSE sequences in the oblique coronal, and sagittal planes for clinical grading. The parameters were 288x244, slice thickness = 3mm, FOV = 14-20cm, BW=50kHz, NEX=3, TR/TE=3000/60ms. Experienced board-certified musculoskeletal radiologists graded the cartilage defects for all subjects on the coronal and sagittal

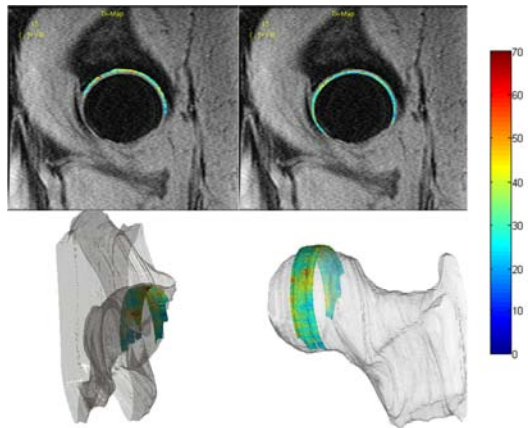
MRI studies. Cartilage defects were graded as 0 (no defect), 1 (partial thickness) and 2 (full thickness) for the femoral and acetabular cartilage. Approximately 60 of the subjects were scanned with a 3D multi-echo SPGR (MERGE) sequence with TR=30.4ms, 5 echo times (effective TE=12.4ms), FA=15°, 512x512, 28 slices, slice thickness=4mm, FOV=14cm, BW=62.5kHz. A concatenated 3D segmented SPGR T1ρ/T2 sequence[5], in which the T2 echoes are acquired immediately after the T1ρ acquisitions, was used for quantification of T1ρ and T2 relaxation times. The scan parameters were time of spin lock [TSL] = 0/15/30/45 msec, spin-lock frequency = 500 Hz; for T<sub>2</sub> preparation: TE = 0/10.4/20.8/41.7 msec; for both for T1ρ and T<sub>2</sub>: FOV = 14 cm, matrix = 256 x 128, views per segment (VPS) = 64, BW = 62.5 kHz, time of recovery = 1.2 sec, slice thickness = 4 mm. The femoral and acetabular cartilage were semi-automatically segmented separately (on the MERGE images when available, on the T1ρ TSL=0 images when not) using an in-house image-processing software program. Examples of the femoral and acetabular T1ρ maps are shown in **Figure 1**. The cartilage was then divided into 8 sub-regions, as shown in **Figure 2**. The mean T1ρ and T2 values in the resulting sub-regions containing cartilage (4 for acetabular, 5 for femoral) were quantified. A multivariate ANOVA test, adjusted for age and BMI, was then performed to compare the T1ρ and T2 values in sub-regions between the subjects with and without femoral and acetabular cartilage lesions.

**Results:** T1ρ and T2 values in the acetabular cartilage subregions for all subject groups are shown in **Figure 2**. After adjusting for age and BMI (which were significantly different between groups), a significantly higher T1ρ relaxation time was seen in region 3, and higher T2 relaxation time was seen in regions 3, 4, and 5, for subjects with acetabular cartilage lesions versus those without lesions. Differences in the T1ρ and T2 relaxation values in the femoral cartilage were not significant when comparing those with and without femoral cartilage lesions.

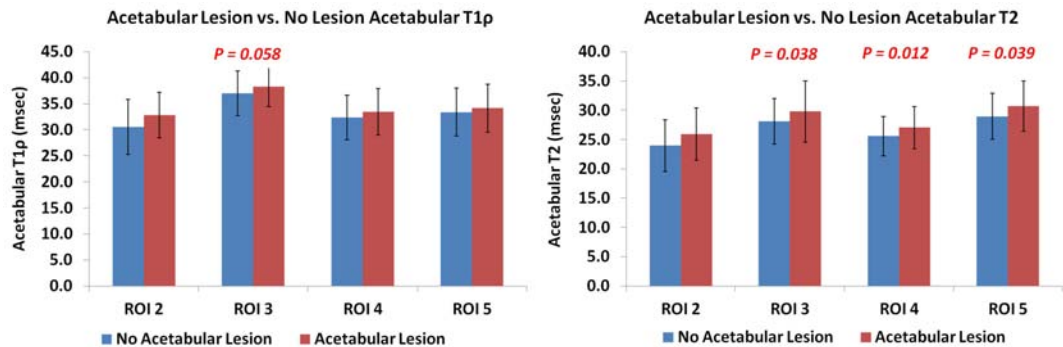
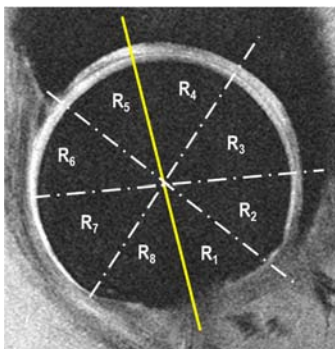
**Discussion:** Elevation of T1ρ and T2 relaxation times in the anterior superior regions of the femoro-acetabular joint (regions 3, 4, and 5) is consistent with earlier studies that have shown greater incidence of cartilage lesions in these regions [6] and greater loading [7]. Acetabular lesions have also been shown to be related to pain and disability. The presence of significant changes in the acetabular and not the femoral cartilage correlates with these clinical findings.

**Conclusions:** This study demonstrates hip cartilage T1ρ and T2 relaxation times to be different in individuals with and without acetabular cartilage lesions.

**References:** [1] Kumar D, et al. 2013; Osteoarthritis Cartilage ;21(11):1685-92 [2]Carballido-Gamio, *JMRI*, 2008, 28:227 [3]Nishii, et al. 16:2 227-233 [4]Rakhra KS *J Bone Joint Surg Br.* 2012 Sep;94(9) [5]Li, X, *JMRI*, 2013. [6]Stelzeneder et al., *Osteoarthritis Cartilage* 2012;20(7):661-669. [7] Harris, et al. 30:7 1133-1139.



**Figure 1:** Representative T1ρ maps and 3D representation of the maps for (left) acetabular and (right) femoral cartilage. Color bar in msec.



**Figure 2:** (a) Representative MERGE image with the multiple regions of segmentation (ROI 1-8); (b) T1ρ relaxation values for those with and without acetabular cartilage lesions. (c) T2 relaxation values for those with and without acetabular cartilage lesions (error bars represent standard deviation)