

Arterial spin labeling perfusion MRI in neonates with hypoxic-ischemic encephalopathy.

Jill B. De Vis¹, Jeroen Hendrikse¹, Esben T. Petersen¹, Linda S. de Vries², Frank van Bel², Thomas Alderliesten², Floris Groenendaal², and Manon J.N.L. Benders²
¹Radiology, University Medical Center Utrecht, Utrecht, Utrecht, Netherlands, ²Neonatology, University Medical Center Utrecht, Utrecht, Utrecht, Netherlands

Introduction and purpose: Impaired autoregulation in neonates with hypoxic-ischemic encephalopathy (HIE) is an indicator of severe brain tissue damage¹. Arterial spin labeling (ASL) MR imaging can depict areas with impaired autoregulation as hyperperfused areas, and an earlier study demonstrated subsequent lesions to occur within these hyperperfused areas². Therefore, hyperperfusion may be a predictor of adverse outcome. The purpose of this study was to investigate whether neonates with an adverse outcome at 9- or 18-months of age had higher perfusion in the basal ganglia and thalami in the first days after birth compared to neonates with a favorable outcome. In addition, we investigated the predictive performance of ASL perfusion for outcome.

Methods: This study was approved by the institutional review board. Twenty-eight (near)- term neonates (gestational age 36 – 42 weeks, birth weight 2340 – 4010 g) with HIE were included. Pulsed star labeling of arterial regions (pulsar)³ MRI was performed at a mean postnatal age of 5 days (range 2 – 7 days), scan parameters were; TR/TE/TI₁(Q₂TIPS⁴)/TI: 2700/17/600/1500 ms, voxel 4x4x7 mm, gap between slices 1mm and multi-slice EPI readout. Quantitative perfusion maps were created based on a T_{1t} of 1.5s, a λ of 0.9, M_{0b} was estimated from the data, and the T_{1b} was derived from hematocrit^{4,5}. Mean perfusion in the basal ganglia and thalami was obtained using region-of-interest analysis (MRico). Outcome was graded as adverse or favorable at 9-months or 18-months of age, with adverse being either death or cerebral palsy. Student's t-tests were used to compare perfusion in the favorable to the adverse outcome group. Receiver operating characteristic curves were created, cut-off values were calculated by using the maximum Youden J index.

Results: Mean perfusion in the basal ganglia and thalami of the neonates with an adverse outcome (69 ± 27 ml/100g/min) was significantly higher compared to neonates with a favorable outcome (31 ± 10 ml/100g/min) (p < 0.01). The area-under-the-curve was 0.92 (95% CI: 0.74-0.99). With a cut-off value of 51 ml/100g/min, the sensitivity, specificity, positive predictive value and negative predictive value of ASL perfusion in the basal ganglia and thalami to predict outcome were 86%, 100%, 100%, and 96% respectively.

Discussion: Neonates with HIE and an adverse outcome had significant higher perfusion in the basal ganglia and thalami. Neonates with adverse outcome were imaged earlier compared to neonates with favorable outcome, this may have exaggerated the perfusion difference between both groups. ASL perfusion in the basal ganglia and thalami had a positive predictive value of 100% and a negative predictive value of 96% for the prediction of outcome in neonates with HIE. However, the cut-off value was derived from our own data which may have lead to an overestimation of the performance of ASL MRI to predict outcome in neonates with HIE. Limitations of the current study are the small sample size and the young age of the infants at follow-up.

References: [1] Pryds O et al. J Pediatr 1990. [2] Wintermark P et al. AJNR 2011. [3] Golay X et al. MRM 2005. [4] Buxton RB et al. MRM 1998. [5] Varela M et al. NMR in biomed 2011.

Acknowledgements: This research is supported by the Dutch technology foundation STW, applied science division of NWO, the technology program of the ministry of economic affairs and the ZonMW electromagnetic fields and health program.

Figure 1: ASL images.

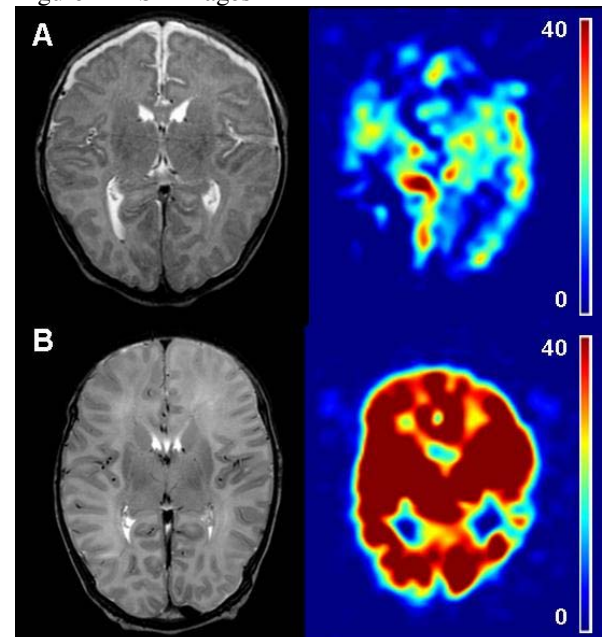


Figure 1: (A) T2-flair –and ASL image of a neonate with favorable outcome. (B) T2-flair –and ASL image of a neonate with adverse outcome (death). Profound hyperperfusion in the entire brain.

Figure 2: ASL perfusion in the basal ganglia and thalami.

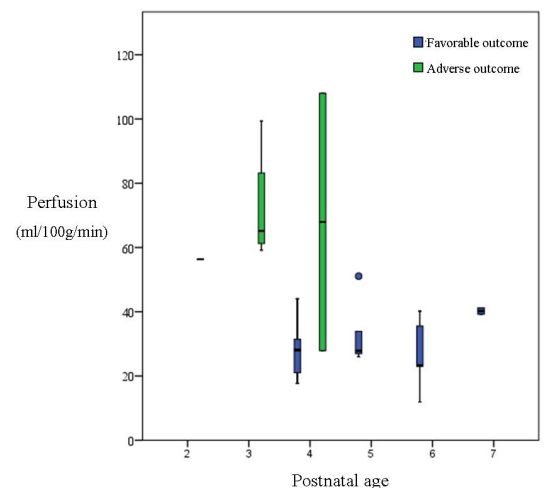


Figure 2: ASL perfusion as a function of outcome and postnatal age. The green color represents the infants with adverse outcome, the blue color the infants with favorable outcome. Infants with adverse outcome were imaged earlier than infants with favorable outcome (p < 0.001) and had higher perfusion in the basal ganglia and thalami (p < 0.01).