

IN VIVO CHARACTERIZATION OF INFLAMMATION BY COMBINED [¹¹C]-PBR28 PET IMAGING AND 7 TESLA MRI IN MULTIPLE SCLEROSIS

Costanza Gianni¹, Audrey Fan¹, Sindhuja Tirumalai Govindarajan¹, Marco Loggia¹, Nicole Zurcher Wimmer¹, Ciprian Catana¹, Jacob Hooker¹, Emanuele Tinelli², Celine Louapre¹, Thomas A Anderson³, R.P. Kinkel⁴, and Caterina Mainero¹

¹Athinoula A. Martinos Center for Biomedical Imaging, Massachusetts General Hospital, Charlestown, MA, United States, ²Neurology and Psychiatry, Sapienza, University of Rome, Rome, Italy, ³Massachusetts General Hospital, Boston, MA, United States, ⁴Beth Israel Deaconess Medical Center, Boston, MA, United States

Target Audience. Neurologists, radiologists, and neuroscientists interested in developing methods to better understand in vivo the relationship between inflammatory and structural pathology in multiple sclerosis.

Purpose. Inflammation through activation of macrophages and microglia is a prominent neuropathological feature in multiple sclerosis (MS). Post-mortem investigations have detected activated microglia in the cortex of MS patients, while histopathological studies have implicated microglia in both white matter (WM) and gray matter (GM) lesion pathogenesis and in diffuse damage of normal appearing WM (NAWM) [1]. To date our knowledge of the relationship between inflammation and structural damage in the brain relies mainly on neuropathological studies. Activated microglia upregulate expression of the 18kDa translocator protein (TSPO), which can be imaged in vivo with [¹¹C]PBR28, a second generation TSPO ligand [2]. Here, we combined [¹¹C]PBR28 imaging on a high resolution, simultaneous human MR-PET system with 7 Tesla (7 T) MRI to investigate the presence of activated microglia and macrophages. Tracer uptake was assessed within different lesional and non-lesional tissue compartments across the brain, relative to healthy subjects.

Methods. Five subjects with secondary progressive MS (3 females, mean±SD age=47.4±7.5 years, mean±SD disease duration=20±9.5 years, median, range Expanded Disability Status Scale Score, EDSS,=7.0,4-7), and five healthy controls matched for age, gender and [¹¹C]PBR28 affinity were recruited for the study. Tracer affinity binding was determined by genetic stratification according to TSPO gene polymorphism [3] (high affinity binder=HAB, and mixed affinity binder=MAB). All subjects underwent 90 minutes of [¹¹C]PBR28 imaging on a unique Siemens BrainPET scanner, a dedicated brain avalanche photodiode based PET scanner that can be operated in the bore of a 3 T whole-body MR scanner. MRI anatomical scans were simultaneously collected for FreeSurfer [4] cortical surface reconstruction and registration between PET and MR modalities. Standard uptake value (SUV) maps were created from averaging PET frames (1.25 mm isotropic voxels) between 60-90 minutes.

Four patients were also scanned on 7 T human scanner (Siemens Medical Systems, Erlangen, Germany), using a 32-channel head coil to acquire multi-echo T2*-gradient-echo sequences (0.33x0.33x1 mm³) with coverage of the supratentorial brain. Cortical (reaching the pial surface), leukocortical (extending across GM and WM without reaching the pial surface) and WM lesions were identified by consensus between two experienced raters, and lesion volumes were measured for all lesion types using Slicer and FSL. In each patient, masks for each lesion type and the NAWM were coregistered to the corresponding [¹¹C]PBR28 map to measure SUV from different brain tissue compartments. SUV values were also obtained from all controls in cortical GM and in WM.

Results. Cortical, leukocortical (LC) and WM lesion volumes (mean±SD) were respectively 7213.48±5235 mm³, 2587.84±2875 mm³ and 11262.10±7522 mm³. SUV values (mean±SD) from GM and WM were 0.765±0.1 and 0.674±0.1 across the control subjects. In patients there was a ~26% increase in SUV values for total GM=1.029±0.2, a ~31% increase for leukocortical lesions=1.082±0.5, a ~25% increase for WM lesions=0.896±0.2, a ~28% increase for cortical lesions=1.067±0.2 and a ~30% increase for NAWM=0.969±0.1. SUV values for healthy subjects and patients according to their affinity binding type are shown in Figure 1. Despite the diffuse increase in [¹¹C]PBR28 uptake across the cortex and WM, in several regions there was a clear spatial overlap with structural cortical, LC, and WM T2* lesions (Figure 2 – 3).

Conclusion. TSPO imaging with [¹¹C]PBR28 disclosed diffuse microglia and macrophage activation across the cortex and WM in a small sample of SPMS, which partially overlapped with visible lesions on 7 T T2* images. Interestingly, diffuse microglia activation was present also in NAWM, and could reflect the diffuse NAWM injury with microglia activation reported by previous neuropathological observations of chronic progressive MS.

References. [1] Lassman H, et al Neurology 2008. [2] Fujita M, et al Neuroimage 2008. [3] Owen DR, et al J Cereb Flow Metab 2012. [4] Dale A, et al Neuroimage 1999. This work was supported by Clafin Award; NMSS RG 4729A2/1; NMSS RG 4281-A-1, FISM Training Fellowship 2012/B/4

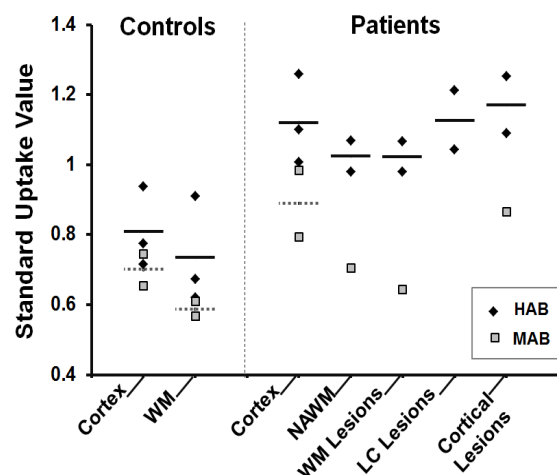


Fig.1 Mean SUV values in individuals; Bars indicate group averages for HAB= High Affinity Binder, MAB= Mixed Affinity Binder

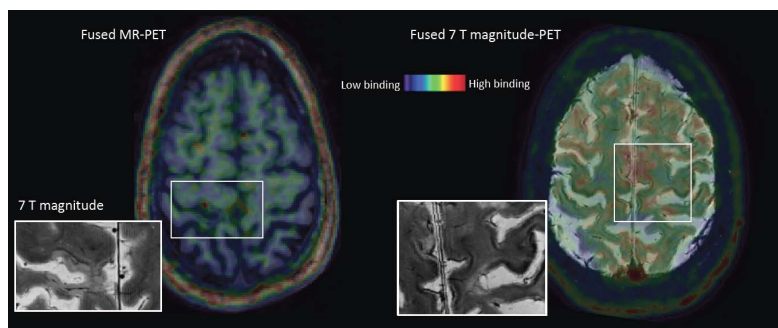


Fig. 2. Summed [¹¹C]-PBR28 PET images coregistered and fused with the 3 T MEMPR anatomical from a male (left) and from the 7 T magnitude image from a female (right) subject with SPMS demonstrating areas of increased radiotracer SUV, which appear topographically associated with the presence of cortical lesions on the coregistered 7 T T2* magnitude images in both patients.

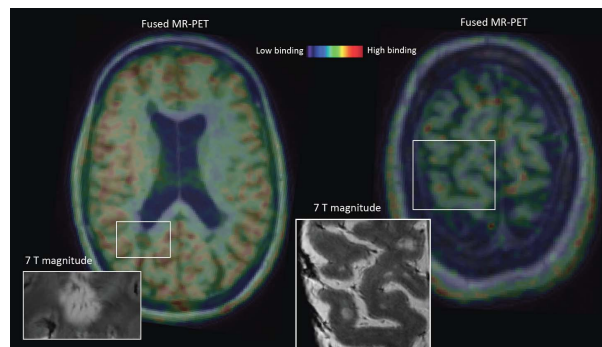


Fig.3. Summed [¹¹C]-PBR28 PET images coregistered and fused with the 3 T MEMPR anatomical from 2 female patients with SPMS. In addition to diffuse tracer binding in the cortex, some areas of increased [¹¹C]-PBR28 uptake overlapped with visible WM lesions on T2* magnitude images.