

ACCURACY AND RELIABILITY OF ASL PERFUSION IN EVALUATING NEURODEGENERATIVE DISEASE: VOXEL-WISE AND CORTICAL-REGIONAL COMPARISON WITH 18F-FDG PET

Steve H Fung^{1,2}, Christof Karmonik^{1,2}, Mario F Dulay^{1,2}, Belen Pascual^{1,2}, Daniel Y Lee^{1,2}, Stephen B Chiang^{1,2}, Ronald E Fisher^{1,2}, Robert G Grossman^{1,2}, Bryan M Spann^{1,2}, and Gustavo C Roman^{1,2}

¹Houston Methodist Research Institute, Houston, Texas, United States, ²Houston Methodist Hospital, Houston, Texas, United States

Target Audience

Radiologists and neurologists using arterial spin labeling (ASL) to assess regional cerebral perfusion pattern in elderly patients evaluated for neurodegenerative disease.

Purpose

Brain FDG-PET is a well-established imaging technique for the diagnosis of Alzheimer's disease as well as differentiation from other causes of dementia. Regional cerebral hypometabolism pattern in Alzheimer's disease generally involves the precuneus/posterior cingulate and lateral parietotemporal cortices; other causes of dementia should be considered if an alternate pattern of regional cerebral hypometabolism is found. Previous studies using perfusion-SPECT and more recently ASL have also shown similar regional cerebral hypoperfusion pattern. Our institution use FDG-PET, ASL, and volumetric MRI in the clinical evaluation of neurodegenerative disease, and we have noted discrepancy between regional cerebral hypoperfusion pattern by ASL and hypometabolism pattern by FDG-PET particularly in the occipital lobe, which can confound differentiation of Alzheimer's disease from dementia with Lewy bodies and Parkinson's disease. Therefore, we formally compared regional and voxel-level cerebral blood flow (CBF) estimated from ASL to standard uptake value (SUV) from FDG-PET, test-retest reliability of CBF from ASL, and CBF from ASL in eyes-open versus eyes-closed states in this patient population.

Methods

Forty-six patients (ages 59-90, M:F 0.73) evaluated for cognitive impairment (including mild cognitive impairment, Alzheimer's disease, frontotemporal dementia, dementia with Lewy bodies, primary progressive aphasia, normal pressure hydrocephalus, vascular and mixed dementia) had brain MRI and FDG-PET within 24 hours. Brain MRI was performed on a 3.0T clinical scanner with CBF (ml/100g/min) estimated using pseudo-continuous ASL (pCASL) with post-labeling delay of 2.5 s. ASL was acquired twice during the 20 min MRI session, once in the beginning and again in the end of the imaging session, to determine test-retest reproducibility of ASL. A subset of patients were instructed to keep eyes open and then closed during the initial and repeat ASL scan, respectively, to test perfusion variability in the visual cortex. High-resolution SPGR images were also obtained for registration of CBF maps and PET images. Brain FDG-PET was performed on a clinical PET/CT scanner 0.75-1.5 hours after intravenous injection of 7.3-11.3 mCi FDG. SUV maps were generated from CT attenuation-corrected PET images. FSL was used for SPGR/ASL/PET/MNI152 standard atlas registration, gray matter (GM) and white matter (WM) segmentation, and image analysis. Voxel-wise and cortical regional comparison between normalized CBF and SUV maps were performed. Absolute and relative CBF difference maps were calculated from initial and repeat ASL scans to determine test-retest reproducibility of ASL at voxel-wise and cortical regional levels.

Results

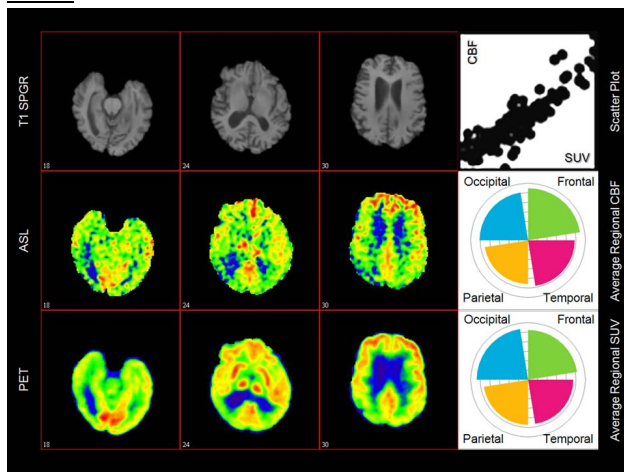


Fig 1. Subject with Alzheimer's disease showing good voxel-wise correlation between ASL CBF and PET SUV. However, note relatively higher SUV than CBF in the occipital lobe on cortical regional analysis.

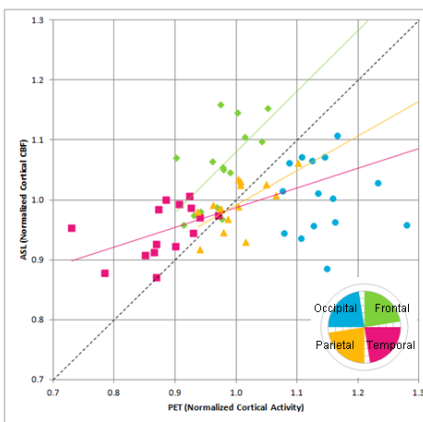


Fig 2. Scatter plot comparing normalized average cortical regional PET SUV and ASL CBF. Good correlation is found between regional SUV and CBF in the frontal, parietal, and temporal lobes. However, occipital CBF tend to be more scattered and underestimated relative to SUV.

Discussion

Aside from the occipital lobe, this study showed good correlation between regional cerebral perfusion on ASL and regional cerebral metabolism on FDG-PET, which is in agreement with previous published studies. In all subjects of this study, FDG-PET activity was consistently highest in the visual cortex in the occipital lobes, whereas occipital perfusion on ASL was more variable. The relatively poor correlation between ASL and FDG-PET in the occipital lobes may be secondary to decreased arterial spin labeling efficiency in the posterior circulation versus physiologic causes. A trend for increased perfusion was noted in the visual cortex in the eyes-open state relative to eyes-closed state, but this observation was not significant within limits of test-retest variance and does not fully account for the relatively poor correlation between ASL and FDG-PET in the occipital lobe.

Conclusion

ASL is a reliable technique for measuring CBF and regional cerebral hypoperfusion pattern for differentiating Alzheimer's disease from other causes of dementia. However, caution should be made in interpreting occipital hypoperfusion with ASL, especially when considering dementia with Lewy bodies or Parkinson's disease, which can have both hypoperfusion and hypometabolism in the occipital lobes. In such cases, occipital hypoperfusion on ASL should be confirmed with occipital hypometabolism on FDG-PET.

References

1. Du AT, Jahng GH, Hayasaka S, et al. *Neurology*. 2006;67:1215-20.
2. Xu G, Rowley HA, Wu G, et al. *NMR Biomed*. 2010;23:286-93.
3. Austin BP, Nair VA, Meier TB, et al. *J Alzheimers Dis*. 2011;26S3:123-33.
4. Chen Y, Wolk DA, Reddin JS, et al. *Neurology*. 2011;77:1977-85.
5. Weih M, Degirmenci U, Kreil S, et al. *J Alzheimers Dis*. 2011;26S3:97-103.
6. Musiek ES, Chen Y, Korczykowski M, et al. *Alzheimers Dement*. 2012;8:51-9.
7. Kim SM, Kim MJ, Rhee HY, et al. *Neuroradiology* 2013;55:25-34.
8. Wang Z, Das SR, Xie SX, et al. *Neuroimage Clin*. 2013;2:630-6.
9. Kilroy E, Apostolova L, Liu C, et al. *J Magn Reson Imaging*. 2013

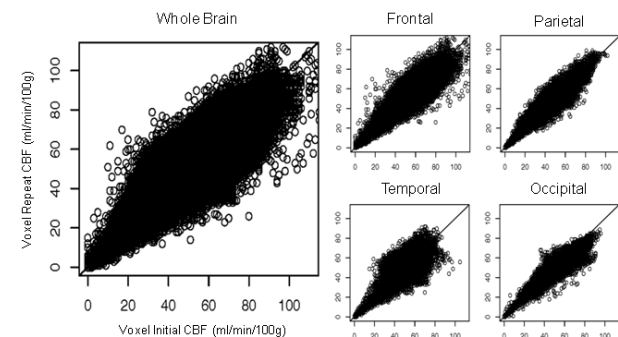


Fig 3. Scatter plots of initial versus repeat CBF for whole brain and cortical regions show good voxel-level reproducibility in all cortical regions, including the occipital lobe. There is a trend for increased perfusion in the visual cortex in the eyes-open state relative to eyes-closed state but is not significant within limits of test-retest variance. Histogram of voxel-wise CBF difference maps are Gaussian. For absolute difference CBF maps, GM mean: -0.11 ± 0.80 , std: 9.8 ± 1.9 ; WM mean: 0.63 ± 0.71 , std: 9.5 ± 2.0 mL/min/100g. For relative difference CBF maps, GM mean: $0.5 \pm 1.7\%$, std: $23 \pm 4\%$; WM mean: $2.6 \pm 1.8\%$, std: $27 \pm 4\%$.