

MICROSTRUCTURAL CHARACTERIZATION OF UNIDENTIFIED BRIGHT OBJECTS IN NEUROFIBROMATOSIS TYPE 1

Thibo Billiet¹, Louise Emsell¹, Felice D'Arco², Sabine Deprez¹, Judith Verhoeven¹, Ellen Plasschaert³, Ronald Peeters¹, Eric Legius³, and Stefan Sunaert¹
¹Radiology, KULeuven, Leuven, Belgium, ²Radiology, University Federico II of Naples, Naples, Italy, ³Human Genetics, UZLeuven, Leuven, Belgium

Introduction:

Neurofibromatosis type 1 (NF1) is a genetic disorder in which expression of the neurofibromin protein is reduced. So-called “unidentified bright lesions” (UBOs, Fig.1), hyperintensities visible on T2-weighted MR images, have been shown to correlate with learning difficulties [1]. Although the exact nature of UBOs is not known, one hypothesis is vacuolization of the myelin sheath. The present in vivo study assesses the microstructure of UBOs making use of diffusion kurtosis imaging and relaxometry.

Materials & methods:

10 NF1 patients were scanned on a 3T Philips Achieva MR scanner. A diffusion scan was acquired (gradient strengths 700, 1000 and 2800 s/mm² along 25, 40 and 75 directions, respectively). Using the ExploreDTI toolbox [2], fractional anisotropy (FA), mean, axial and radial diffusivity (MD, AD, RD) were estimated, as well as kurtosis anisotropy (KA), mean, axial and radial kurtosis (MK, AK, RK).

A 3D GraSE 32-echo sequence (TE=10, 20, ..., 320 ms) [3][4] was acquired for calculation of relaxometry parameters: myelin water fraction (MWF), intra- and extracellular water fraction (IEF), geometric mean T2 (gmT2) and peak width of resulting T2 distribution peaks [5].

Regions of interest around 20 UBO sites and contralateral NAWM were drawn on T2-weighted FLAIR (Fig. 1), brought to the relevant image space (b0-image for diffusion and mean echo image for relaxometry) and average parameter values were obtained. A Wilcoxon signed ranks test was applied for statistical analysis.

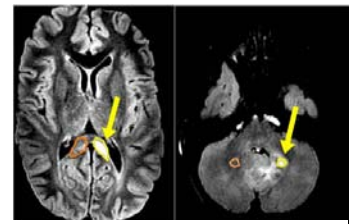


Fig. 1 UBO (yellow) and contralateral NAWM (orange) on T2-weighted image

Results:

See Table 1. Significant increase in UBOs compared to NAWM was found for MD, RD, gmT2 of IE-peak and IE peak width (Fig.2). Significant decrease in UBOs compared to NAWM was found for FA, MK, RK and KA. No significant changes were found for AD, AK, MWF, IEF.

	KA	MK	RK	AK	FA	MD	RD	AD	MWF	M-gmT2	IEF	IE-gmT2	IE-PW
Z	-3.319	-2.833	-2.868	-1.025	-3.354	-2.833	-3.041	-1.894	-0.459	-0.663	-0.255	-2.803	-1.988
P	0.001*	0.005*	0.004*	0.305	0.001*	0.005*	0.002*	0.058	0.646	0.508	0.799	0.005*	0.047*

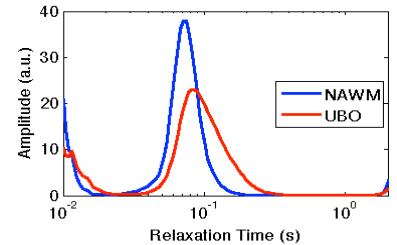


Fig.2 UBO sites show an increased peak width and gmT2 in the T2-distribution

Table 1. Z-scores and P-values of paired comparison between 20 UBOs and contralateral NAWM. *=significant at 95%-level

Conclusion:

Both diffusivity and kurtosis in radial directions were found altered in UBOs compared to NAWM, indicating the existence of different diffusional compartments [6](Jensen and Helpert 2010), possibly intramyelinic edema. We did not find diffusional alterations in the axial direction. Although the elevated RD and decreased RK we found were previously seen as indicators of myelin breakdown and debris formation [7], no significant difference in myelin water fraction (MWF) was found in UBOs compared to NAWM.

The hypothesis of intramyelinic vacuolization is further confirmed by the broadening of the intra- and extracellular water peak (IE-PW) and geometric mean T2 time (IE-gmT2). These are indicators of edema formation [8].

[1]Piscitelli, O., M. C. Digilio, et al. *Dev. med. ch. neur.* 54(1): 49-51 (2012) [2] Leemans, A. *Proc. Intl. Soc. Mag. Reson. Med.* (2009) [3] Madler, B., S. A. Drabycz, et al. *Magnetic resonance imaging* 26(7): 874-888 (2008) [4] Prasloski, T., A. Rauscher, et al. *Neuroimage* 63(1): 533-539 (2012) [5] MacKay, A., C. Laule, et al. *Magnetic resonance imaging* 24(4): 515-525 (2006) [6] Jensen, J. H. and J. A. Helpert, *NMR in biomedicine* 23(7): 698-710 (2010) [7] Hui, E. S., M. M. Cheung, et al. *Neuroimage* 42(1): 122-134 (2008), [8] Vavasour, I. M., C. Laule, et al. *J. M.R.M.* 33(3): 713-718 (2011)