

## Diffusion Tensor Imaging of Acute Axonal Degeneration following Neonatal Cerebral Hypoxia-Ischemia in Rats

Ursula I. Tuor<sup>1,2</sup>, Melissa Morgunov<sup>1</sup>, Manasi Sule<sup>1</sup>, Min Qiao<sup>1</sup>, Tadeusz Foniok<sup>2</sup>, and Adam Kirton<sup>3</sup>

<sup>1</sup>Physiology and Pharmacology and Clinical Neurosciences, University of Calgary, Calgary, Alberta, Canada, <sup>2</sup>Experimental Imaging Centre, University of Calgary, Calgary, Alberta, Canada, <sup>3</sup>Pediatrics and Clinical Neurosciences, University of Calgary, Calgary, Alberta, Canada

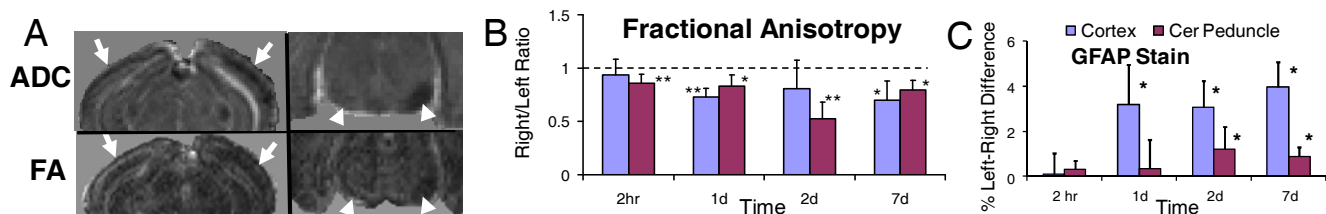
**Target Audience:** Clinicians and Basic Scientists using Diffusion Tensor Imaging.

**Purpose:** To determine regional differences in diffusion tensor parameters and histological changes at acute and subacute times (2 hours to 7 days) following transient hypoxia+unilateral cerebral ischemia in neonatal rats.

**Background:** Cerebral hypoxia-ischemia (HI) in neonates is an important cause of perinatal brain injury and cerebral palsy. Standard magnetic resonance imaging has been used to detect acute changes in the descending cortico-spinal tract (DCST) and changes have correlated with motor outcome<sup>1</sup>. Unknown is whether acute MRI changes (e.g. T2 and ADC) associated with signs of early Wallerian degeneration<sup>2,3</sup>, correspond to diffusion tensor imaging (DTI) changes considered sensitive to ultrastructural changes in brain. We hypothesized that DTI would provide additional insights into the acute microstructural changes in axons remote to cortex damaged by cerebral HI.

**Methods:** Wistar rats (7 day old) were exposed to either a sham surgery (control) or a transient cerebral hypoxia+unilateral ischemic episode (carotid artery ligation + transient hypoxia (8%O<sub>2</sub>)). Animals (n=6-8/group) were imaged at various times following hypoxia (2hr, 1d, 2d and 7d post-surgery) using a 9.4T MRI system (Bruker Biospin). A DTI echo-planar imaging sequence (b of 1000, 30 directions) was used to obtain measures in ipsilateral and contralateral regions of interest: e.g. (ischemic) parietal cortex, cerebral peduncle of the descending corticospinal tract and pons (latter regions remote from the ischemia). Fractional anisotropy (FA), diffusion trace, and eigenvalues were converted to ipsilateral/contralateral ratios. Immediately after imaging, brains from subgroups were processed for histological analysis of sections immuno/stained with myelin basic protein antibody (MBP), neurofilament antibody, glial fibrillary acidic protein antibody (GFAP) for reactive astrocytes and ED1 antibody for activated microglia/macrophages.

**Results:** In the pons, DTI parameters (FA, mean diffusivity and eigenvalues) and histological stains were generally not affected by HI. In the ipsilateral ischemic cortex, DTI parameters had marked early changes ipsilaterally (e.g. Fig), that recovered by 7d post-insult except for FA. In the cerebral peduncle, changes in DTI parameters were modest at 2hr (i.e. a decrease in FA, ADC and eigenvalue<sub>1</sub>). These changes became pronounced at 1 and 2 days post HI with normalization by 7 days except for FA. White matter tractography of the DCST resulted in a reduced number of fibers detected ipsilaterally in the DCST at 2hr-2d post HI, although mean DTI values were similar to those in controls. MBP staining was similar ipsilateral and contralaterally. Cortical increases in staining for ED1 were observed at 2hr and 1w post. GFAP staining was increased by 1 d post HI in cerebral cortex and by 2 d in cerebral peduncle (Fig). Neurofilament staining was reduced in cerebral peduncle at acute time points.



**Fig.** DTI and histology following hypoxia ischemia in rat pups. **A.** Representative maps of the mean diffusivity (ADC) and FA at 1 day post-insult demonstrates decreases in ADC and FA in ischemic(right) cerebral cortex (arrows) or cerebral peduncle (arrow head). Also shown are the mean ipsilateral vs contralateral differences for FA (**B**) and GFAP (**C**) staining. \* $P < 0.05$ ; \*\* $P < 0.005$ .

**Discussion:** ADC changes are comparable to those reported previously using standard imaging sequences (T2,ADC)<sup>2,3</sup> and eigenvalue changes measured using DTI. In contrast to these DTI parameters that normalized or increased to above control values by 7d, FA ratios remained reduced at all times. The ‘fibers’ detected with tractography were also reduced at all time points examined, corresponding to reduced neurofilament staining. Acute (2hr-1d) DTI changes in cerebral peduncle were not associated with changes in staining for myelin, microglia/macrophages or reactive astrocytes.

**Conclusion:** Axonal changes in the cerebral peduncle of the DCST can be detected within hours following a unilateral HI injury using standard imaging and DTI. FA detects well axonal degenerative changes at acute and subacute time points.

**Acknowledgements:** Supported by Heart and Stroke Fndn, Markin USRP and Alberta Innovates Health Solutions.

**References :** (1) Domi T, deVeber G, Shroff M, Kouzmitcheva E, MacGregor DL, Kirton A. Corticospinal tract pre-wallerian degeneration: A novel outcome predictor for pediatric stroke on acute MRI. *Stroke* 2009;40:780-7.

(2) Lama S, Qiao M, Kirton A et al. Imaging corticospinal degeneration in neonatal rats with unilateral cerebral infarction. *Exp Neurol* 2011 228:192-9.

(3) Tuor UI, Qiao M, Morgunov M, Fullerton E, Foniok T, Kirton A. Magnetization Transfer and Diffusion Imaging of Acute Axonal Damage in the Cerebral Peduncle following Hypoxia-Ischemia in Neonatal Rats. *Ped Res*, in press, 2012.