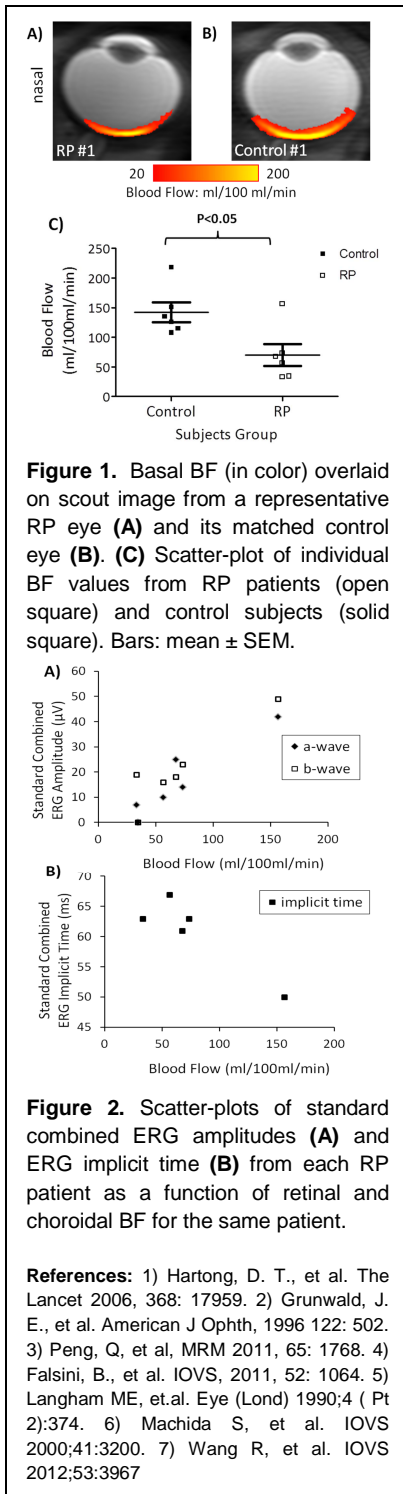


Decreased Retinal and Choroidal Blood Flow by MRI is Correlated with Electroretinography in Retinitis Pigmentosa

Yi Zhang¹, Joseph Harrison², Oscar San Emeterio Nateras¹, Steven Chalfin², and Timothy Duong^{1,2}

¹Radiology, University of Texas Health Science Center at San Antonio, San Antonio, TX, United States, ²Ophthalmology, University of Texas Health Science Center at San Antonio, San Antonio, TX, United States



Purpose: Retinitis pigmentosa (RP) is a heterogeneous hereditary disease characterized by photoreceptor degeneration¹. The goal of this study was to explore a novel application of MRI to study retinal and choroidal BF in patients with RP, and to determine whether BF change is associated with visual dysfunction in the same RP patients. To improve the sensitivity of BF measurement, pseudo-continuous arterial spin-labeling technique (pCASL) with static tissue suppression and single-shot turbo-spin-echo (TSE) acquisition were implemented. A custom-made receive-only eye coil was utilized to improve signal-to-noise ratio on a 3-Tesla clinical MRI scanner. The full-field ERG provided an objective measurement of retinal function.

Methods: MRI studies were performed in 6 RP patients (29-67 years) and 6 gender- and age-matched healthy volunteers (29-64 years) on a 3-Tesla scanner with a custom-made surface coil. Quantitative BF³ was measured using pCASL and single-shot TSE as acquisition. pCASL had labeling duration = 2000 ms, post-labeling delay = 1500 ms and a labeling plane 7 cm inferior to the imaging plane. TSE acquisition had TR/TE=4.6s/30ms, slice thickness=6mm, FOV=50x43mm (resolution=500x800 μ m). Automated profile analysis⁵ was performed to identify the retina and obtain BF profiles. BF over a posterior part of the retina and choroid (\pm 5 mm centered at the macula) was averaged.

Visual function was tested using full-field electroretinography (ERG). Amplitudes and implicit times of standard ERGs were analyzed. Two-tailed Mann-Whitney test was used to compare BF values of the RP and control groups. Correlations between the individual BF values and ERG parameters were evaluated by nonparametric Spearman's rank correlation.

Results: Figure 1A, B shows a BF MR image from a RP retina and a matched control. BF peaked at the posterior pole of the retina and dropped significantly at the distal edges of the retina. BF of the RP retina was lower compared control. Figure 1C shows the scatter-plot of individual BF values for RP patients and control subjects. Averaged BF was 70 ± 19 ml/100ml/min in RP retinas and was 142 ± 16 ml/100ml/min in control retinas, a reduction of $52 \pm 8\%$ in RP ($P < 0.05$).

Full-field ERGs of RP retinas were abnormal compared to those of non-RP retinas with reduced a-wave and b-wave amplitudes and prolonged b-wave implicit time. In RP retinas, reduced BF values were positively correlated with reduced ERG a-wave amplitude ($r=0.9$, $P < 0.05$), and with b-wave amplitude ($r=0.7$, $P=0.17$) (Figure 2A). BF and ERG b-wave implicit time showed a negative correlation ($r=-0.7$, $P=0.23$) (Figure 2B).

Discussion: BF from a posterior retina and choroid was significantly reduced in RP patients compared with age- and gender-matched control subjects. Reduced BF is consistent with the fundus observation of attenuated retinal vessels in the same RP patients. Our result is also in agreement with previous studies indicating that ocular blood circulation is altered in RP^{2, 4-5}.

ERG amplitudes have been shown to correlate with remaining photoreceptor counts in P23H rhodopsin transgenic rats⁶ (the P23H mutation of opsin is a common mutation causing RP in humans) and in Rho^{-/-} mice⁷. The correlations between BF and ERG amplitudes found in this present study may reflect pathological changes in vasculature systems.

Indeed, several previous studies demonstrated similar correlations between circulatory parameters and visual function. Subfoveal choroidal BF alteration was linked to RP-associated central cone-mediated dysfunction as assessed by focal ERG. Ocular pulse amplitude, an indirect measure of choroidal perfusion, was significantly correlated with visual-field area measured by Goldmann perimetry in RP patients.

Conclusions: Retinal and choroidal BF was significantly reduced in RP patients compared with matched controls. BF in RP was also correlated with maximal ERG amplitudes, suggesting a link between the hemodynamic dysfunction and the progressive neural degeneration. Future studies will improve spatial resolution to visualize retinal and choroidal BF separately, include BOLD functional MRI of visual function and three-dimensional BF MRI. MRI has the potential to provide unique, clinically relevant, and depth-resolved information for early detection, disease staging and testing novel therapeutic strategies in RP and other retinal diseases.