

# WHOLE-HEART QUANTIFICATION OF MYOCARDIAL PERFUSION WITH SPIRAL PULSE SEQUENCES

Yang Yang<sup>1</sup>, Sujith Kuruvilla<sup>2</sup>, Christopher Kramer<sup>2,3</sup>, Craig Meyer<sup>1,3</sup>, and Michael Salerno<sup>2,3</sup>

<sup>1</sup>Biomedical Engineering, University of Virginia, Charlottesville, VA, United States, <sup>2</sup>Medicine, University of Virginia, Charlottesville, VA, United States, <sup>3</sup>Radiology, University of Virginia, Charlottesville, VA, United States

**Introduction** First-pass perfusion imaging using cardiac magnetic resonance (CMR) is an important tool for diagnosing coronary artery disease (CAD). There is a growing interest in obtaining quantitative, observer-independent, and reproducible measures of myocardial perfusion [1]. Whole heart coverage will be important for determining the percentage of ischemic myocardium, which may have implications for determining the need for revascularization in patients with CAD. Spiral pulse sequences have multiple advantages for myocardial perfusion imaging including high acquisition efficiency, high signal to noise (SNR) and robustness to motion. We have developed an accelerated spiral pulse sequence using the parallel imaging and compressed sensing technique (L1-SPIRiT) [3][4] with an integrated single-shot arterial input function (AIF) capable of performing absolute perfusion quantification with whole heart coverage.

**Methods:** Our previously optimized spiral pulse sequence [2] was modified to achieve 4x acceleration and additionally acquire proton density (PD) and arterial input function (AIF) images for quantification (Figure 1). The PD images were collected in the first 4 heart beats without a saturation pulse using a 5° flip angle (FA). The AIF was acquired during the saturation recovery time (SRT) of the first myocardial perfusion image, thus adding no additional imaging time to the sequence. We then used a 4x accelerated pulse sequence which prospectively collected only 2 of 8 interleaves, and collects two slices after each saturation pulse in an interleaved fashion permitting the use of a higher flip angle of 45 degrees. Perfusion images were acquired on a 1.5T Siemens Avanto scanner during injection of 0.1mmol/kg of Gd-DTPA using a 32 channel coil. Sequence parameters included: TE 1.0ms, TR 18ms, SRT 80ms FA 45°, 2 slices per saturation (27ms temporal resolution per image), 8 slices to cover the whole myocardium, FOV 320mm<sup>2</sup>, in-plane resolution 2.1mm. AIF images were acquired with a 2x accelerated single-shot spiral acquisition using a 90° FA with the following parameters: in-plane resolution 6.95mm, SRT 10ms. Imaging was performed in 5 subjects. Perfusion images were first reconstructed using an iterative conjugate gradient algorithm including a data fidelity term, SPIRiT calibration consistency term and an L1-finite difference in time as the sparsifying transform, then perfusion images were normalized by the PD images

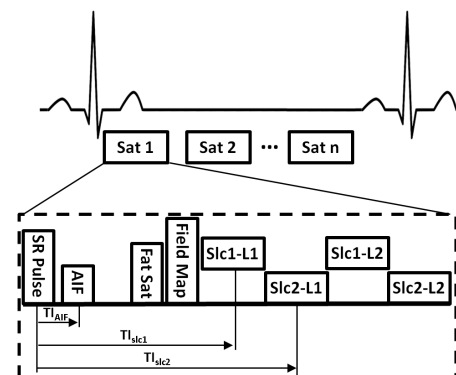


Figure 1. Schematic of the spiral absolute quantification dual sequence.

and Bloch simulation was used to convert to absolute concentration-time curves prior to Fermi-function deconvolution. Reconstruction and quantification of perfusion images were performed in MATLAB.

**Results:** Figure 2 shows L1-SPIRiT reconstructed perfusion images acquired with the proposed pulse sequence with 8 slices covering the ventricular myocardium. The images demonstrate high SNR and no dark-rim artifacts. Figure 3 shows the concentration-time curves from the AIF and TF and representative perfusion maps from one of the subjects. The mean absolute blood flow was 1.019±0.215 mL/g/min, close to the 1 mL/g/min expected for a healthy volunteer at rest.

**Discussion:** The 4x accelerated spiral perfusion sequence, which acquires two perfusion images per saturation in an interleaved fashion, enables full heart quantitative perfusion coverage in 480ms (120 ms for each saturation) supporting a maximum heart rate of 125bpm, which is sufficient for vasodilator stress CMR. Using slice interleaved acquisition, the data for each image is acquired in a 27 ms (18ms in non-interleaved mode) temporal window eliminating motion induced dark-rim artifacts. Collecting two images in an interleaved rather than sequential

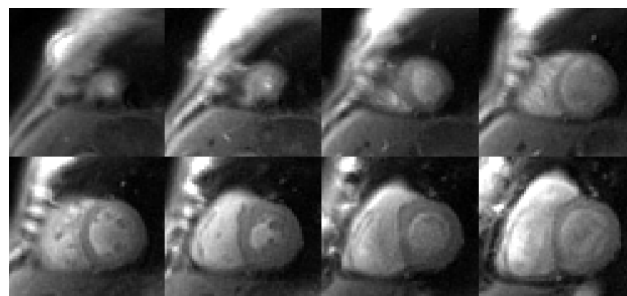


Figure 2. Whole-ventricular coverage perfusion images from one healthy subject.

mode increases the effective TR from 9ms to 18ms, which results in an optimal flip angle of 45 degrees instead of 30 degrees increasing available transverse magnetization (and SNR) by 39%. The effective SRT of the two images only differ by 9ms, so contrast in the images is visually similar and this small difference in SRT is accounted for during quantification

**Conclusion:** We demonstrated the successful application of whole ventricular coverage absolute quantitative first-pass myocardial perfusion imaging using accelerated spiral scanning in healthy volunteers. This sequence can acquire 8 short axis slices in 480ms enabling full ventricular coverage at heart rates up to 125 BPM. Further validation will be required in patients undergoing vasodilator stress CMR.

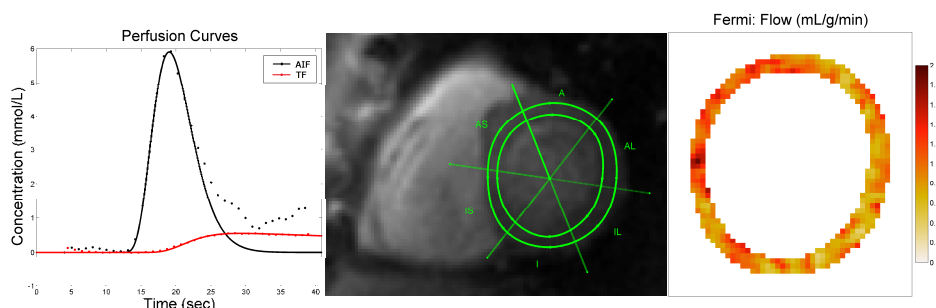


Figure 3. Perfusion time profile of AIF and TF (left), segment ROI (middle) and pixel-based perfusion map from that ROI.

## Reference:

- [1] Jerosch-Herold, JCMR 12: 57
- [2] Salerno et al. MRM 65:1602-1610(2011)
- [3] Lustig et al. MRM 58:1182-1195(2007)
- [4] Lustig et al. MRM 64:457-471(2010)
- [5] Lustig et al. Proc. Intl. Soc. Mag. Reson. Med. 17 (2009)

**Acknowledgements:** Research Support from Siemens Healthcare, AHA 10SDG2650038, NIH K23 HL112910-01, NIH R01 HL079110