

High Throughput Cardiac MRI using Interleaved Breath-Hold Cardiac Cine and Free-Breathing Coronary MR Angiography: Initial Results

Markus Henningsson¹, Reza Nezafat², Peter Koken³, Giel Mens⁴, and Rene Botnar¹

¹Division of Imaging Sciences and Biomedical Engineering, King's College London, London, United Kingdom, ²Harvard Medical School, Boston, MA, United States, ³Philips Research, Hamburg, Germany, ⁴Philips Healthcare, Best, Netherlands

Introduction: Respiratory motion is a common source of artefacts in cardiac MRI¹. To suppress respiratory motion either breath-holds (BH) or free breathing (FB) navigated scans can be employed. For example, for coronary artery disease a coronary MR angiogram (CMRA) is typically acquired in FB (3-8min scan time), while cardiac function is assessed using cardiac cine acquired with multiple BH (10-12sec scan time per BH). Each BH is followed by a period of recovery when the patient rests between subsequent BH and no data are acquired. This results in low scan efficiency. Recently, it has been shown that acquiring additional auxiliary data during the recovery period can be used to improve BH cine scans². In this work we have developed a framework for interleaving BH and FB scans to acquire multiple BH 2D cardiac cine slices and a FB 3D whole heart CMRA dataset in between BH to reduce the overall acquisition time.

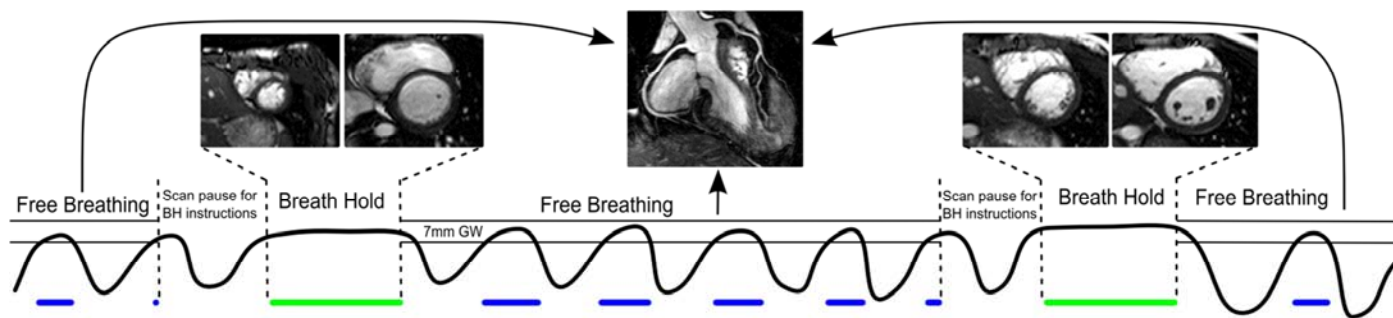


Figure 1. Multiple breath-holds, six in total, were performed to acquire twelve 2D cardiac cine slices covering the left ventricle. In between the breath-holds an ECG-triggered, segmented 3D whole heart CMRA dataset was acquired during free breathing. GW=respiratory gating window; BH=breath hold.

Methods: The proposed acquisition strategy for the interleaved multiple BH 2D cine and 3D high resolution FB CMRA acquisition is shown in Figure 1. The stack of 2D cine images was acquired covering the left ventricle in short axis. In total 12 slices were acquired over 6 BH (2 slices/BH) with the following imaging parameters: FOV=320×320×8mm³, $\Delta x=2\times 2\text{mm}^2$, $\Delta t=30$ cardiac phases, $\alpha=60^\circ$, TR/TE=2.7/1.34ms. The nominal scan time for the 6 BH cine scan was 1:12mins. The ECG-triggered FB CMRA scan was segmented and divided to be acquired between the 6 BH pauses. Each pause was defined as 30 cardiac cycles, which was used to acquire *k*-space segments of the CMRA scan. The imaging parameters for the CMRA scan included: FOV=300×300×100mm³, $\Delta x=1\times 1\times 2\text{mm}^3$, $\alpha=70^\circ$, TR/TE=4.6/2.3ms, SENSE factor=3.5. The nominal scan time of the 3D CMRA was 2:23mins. A navigator was used for the CMRA for respiratory gating (7mm window) and slice tracking (0.6 tracking factor). The end-expiratory position was determined from a navigator preparation phase which was performed before the first breath-hold. 6 healthy subjects were scanned on a 1.5T scanner (Achieva, Philips Healthcare) with a 32-channel cardiac coil.

Results: All subjects successfully completed the scan protocol. No artefacts were observed as a result of scan interleaving. Example images from one healthy subject are shown in Figure 2. The average scan time for the interleaved cardiac cine and CMRA scans were 5:57±0:37mins. The average gating efficiency for the FB CMRA scan was 52%, which would result in a scan time of 4:35mins without scan interleaving for the CMRA scan. Assuming 0:30min recovery between BH, the cine scan would take 4:12mins, resulting in a total scan time of 8:47mins for the two scans without scan interleaving.

Discussion and Conclusion: The total scan time of the proposed interleaved BH cine and FB CMRA scan was almost 50% less than without interleaving. This acquisition strategy allows for higher throughput in cardiac MRI as otherwise unused time between BH can be used to acquire FB data. In clinical cardiac MRI examinations, most of the time is being spent with the patient in FB, even if the majority of scans are BH. The proposed method therefore has a great potential to improve patient throughput in cardiac MRI by enabling a more efficient use of BH and FB sequences. Although in this study we used BH cine and FB CMRA, the proposed framework supports any combination of scans for the BH and FB acquisition. Further studies will explore the use of interleaving other FB and BH scans and evaluate its potential to increase cardiac MRI throughput in clinical practice.

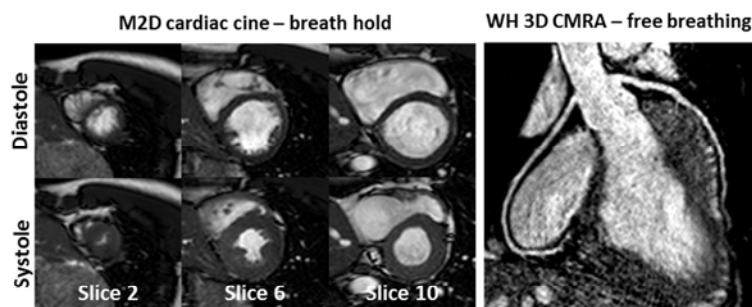


Figure 2. Interleaved multiple 2D cardiac cine and whole heart 3D coronary MRA acquired in 5mins, 42 sec. The cine scan was acquired over 6 breath holds, while the coronary scan was acquired in the free-breathing period between the 6 breath-holds.

References: ¹Scott AD, Radiology, 2009. ²Nam S, JRMI (under review), 2012.