

Preventing unwanted blurring due to incomplete breath-hold at long breath-hold coronary MRA; Usefulness of new elliptical centric acquisition (CENTRA plus)

Hideo Ono¹, Masami Yoneyama¹, Taro Takahara², Thomas Kwee³, Masanobu Nakamura¹, Takashi Tabuchi¹, and Masaharu Hirano⁴

¹Yaesu Clinic, Tokyo, Japan, ²Tokai University School of Engineering, Kanagawa, Japan, ³University Medical Center Utrecht, Utrecht, Netherlands, ⁴Tokyo Medical University Hospital, Tokyo, Japan

Introduction: Cardiac disease is responsible for 13% of deaths in adults worldwide (1). Control of angina is important to prevent the onset of myocardial infarction. Coronary angiography is the gold standard for the evaluation of coronary artery disease (CAD), but is invasive and may cause complications such as arrhythmia, thromboembolism, or renal dysfunction. Whole heart coronary MRA (WHCMRA) is a promising noninvasive method for diagnosing CAD (2). Navigator-gated free-breathing technique has become the method of choice to obtain high-resolution WHCMRA images. Nevertheless, it potentially suffers from long acquisition time. Recently, single breath-hold WHCMRA (SBH-WHCMRA) has emerged thanks to the acceleration of data acquisition with parallel imaging by means of multi-channel coil systems (3) (4). However, the limited scan time during the breath-hold period results in poor signal-to-noise ratio (SNR) and spatial resolution. We may be able to get higher resolution images with longer scan times of, for example, around 30 sec, but this kind of protocol is unrealistic and reduces the success rate of the examination in case of incomplete breath-holding. When we imagine the situation of an incomplete breath-hold, the failure of the breath-hold (i.e., diaphragmatic drift) should occur in the latter half of the scanning. Our hypothesis is that the new method of ellipsoid centric acquisition (CENTRA plus) (5) may be tolerable for this kind of fail in breath-hold which happens in the latter half of the scanning. The purpose of this study was to confirm the advantage of CENTRA plus (CENTRA+) over the conventional method (low-high radial sampling) for the depiction of coronary arteries in a long scanning time.

Materials and Methods: Theory: segmentation schematics in Ky-Kz space of a conventional radial segmentation (low-high radial) are shown in Fig.1a. From each Ky-Kz segment, a profile is acquired per shot starting from the central Ky-Kz segment. Consequently, any timing motions of the imaging time influence the image quality. On the other hand, with CENTRA+, acquisition is started in the central k-space sector and the most central k-space sector is acquired at an early stage (Fig.1b); hence, we hypothesized less influence of motion on the latter half of the imaging time with this technique.

Experiment: This study was approved by the ethics committee of our hospital. Five healthy volunteers were examined on a clinical 1.5T MRI scanner (Achieva 1.5T PHILIPHS Healthcare) using a cardiac 32ch coil. The conventional low-high radial approach and the CENTRA+ approach were acquired in random order. The volunteers held their breath in the first half period and then breathed freely during the latter half. Thus, in CENTRA+, the central part of k-space was acquired during the breath-hold period, whereas the outer k-space profiles were acquired during the subsequent free-breathing acquisition period. Coronary MRA was acquired using a 3D balanced SSFP sequence. The imaging parameters were as follows: TR/TE of 4.0ms/2.0ms, flip angle of 90° matrix of 228×187, T2-prep of 50ms×4, and slice thickness of 1mm (reconstruction of 0.5mm).

Evaluation: For the evaluation the sharpness of coronary arteries, the 20% and 80% points between the maximum and background signal intensities were first calculated for each side of the intensity profile. The distance in millimeters between the two points was then determined for each side. The inverse of the averaged distance of the two sides was used as a measurement of the coronary arterial sharpness. The greater the sharpness, the better the vessel definition (6). Measurement points were the proximal segment of the LAD and the distal segment of the RCA. Paired t-tests were performed, and p-values < 0.05 were considered statistically significant.

Results: The attempted breath-hold at initial half of the imaging time was successful in all volunteers. Effective scan time was 33.8±3.3 sec. Representative MPR images of LAD with each method are shown in Fig.2. Sharpness score was 0.34±0.05 (LAD) and 0.39±0.10 (RCA) with CENTRA+, and 0.30±0.05 (LAD) and 0.34±0.09 (RCA) with low-high radial. CENTRA+ was significantly superior to low-high radial (p<0.05) (Fig.3).

Discussion: In CENTRA+, the most central k-space sector is acquired only at the early stage; the most reliable period of breath-hold. The latter half data may be acquired with poor breath-hold, but it hardly affects the image quality because such data only fill the peripheral k-space. On the other hand, since low-high radial technique acquires the central part of k-space throughout the acquisition, it causes blurring by the poor breath-holding which may happen at the end of long acquisition.

Conclusions: CENTRA+ was superior to the conventional method for the visualization of coronary arteries when a long acquisition was applied with artificially unsuccessful breath-hold at the latter half of the scanning. CENTRA+ may be used for the prolongation of scan time in order to increase the spatial resolution.

References: (1) The 10 leading causes of death by broad income group (2008) : Fact sheet N°310(WHO) (2) Oliver M. Weber, et al. MRM 50:1223-1228 (2003) (3) Thoralf Niendorf, et al. MRM 56:167-176 (2006) (4) Jian Xu, et al. JCMR 12: p47 (2010) (5) Gabriele M.Beck,MS, et al., JMRI 27:1461-1467(2008) (6) Dabiao Li, PhD, et al., Radiology 219:270-277(2001)

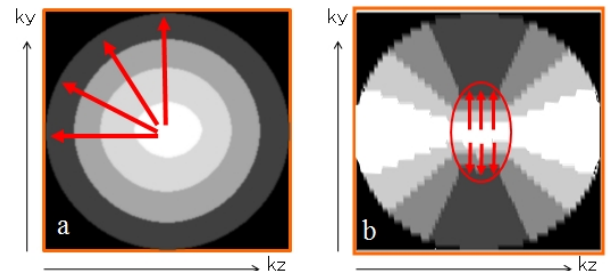


Fig.1. Schematic of k-space acquisition scheme, low-high radial (a) and CENTRA+ (b).

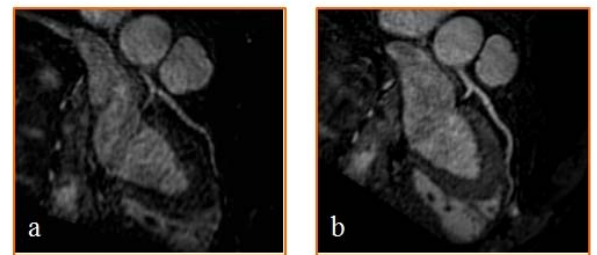


Fig.2. Reformatted images of the LAD acquired with low-high radial (a) and CENTRA+ (b). CENTRA+ is superior in sharpness of the image.

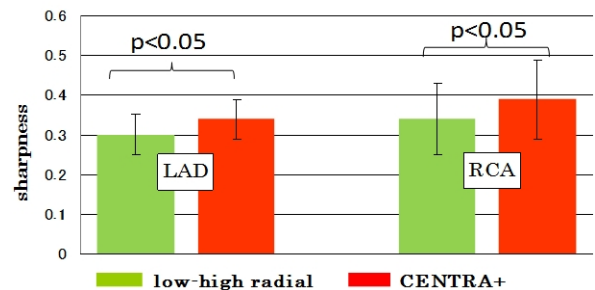


Fig.3. Sharpness of artery; low-high radial and CENTRA+.