

Non-contrast High Resolution MR Venography of Lower Extremity Perforating Veins

Jun Isogai¹, Takashi Yamada², Tomoko Miyata³, and Mitsue Miyazaki⁴

¹Shuwa General Hospital, Kasukabe, Saitama, Japan, ²Hasuda Hospital, Hasuda, Saitama, Japan, ³Toshiba Medical Systems Corp., Saitama, Saitama, Japan, ⁴Toshiba Medical Research Institute, Vernon Hills, IL, United States

Purpose

The aim of our study is to selectively visualize perforating veins of the lower extremity without contrast media and exhibit age-related vasodilatation. The anatomical knowledge of perforating venous system has potential application for variceal ablation procedures. Non-contrast MR angiography was investigated for depicting complex perforating venous systems.

Methods

All studies were performed on 30 healthy volunteers without superficial lower-limb varicosities (mean age, 42.5; range, 24-64 years; 10 men and 20 women) on a 1.5T MRI system, using a knee coil. The ECG-gated 3D half-Fourier FSE method was performed for assessment of thigh and calf perforating veins and compared to other non-contrast MRA techniques, including time-of-flight (TOF), time-spatial labeling inversion pulse (time-SLIP) MRA using on-and-off alternate acquisitions and balanced steady-state free precession (bSSFP) technique. Typical scan parameters as follows; TR/TE=3RR(2000-3000)/80ms, matrix=256x256, FOV=210x210mm, section slice=1mm, and scan time=10min, depending on the volunteer's RR time.

Results

Selective visualization of perforating veins in the thigh and calf was successfully achieved in all volunteers. Half-Fourier FSE MRA showed excellent depiction of complex venous plexus and age-related tortuous and dilated veins and oriented in the cranial direction with aging, as showing in Fig. 1. On the contrary, TOF method depicted substantial portions of deep and superficial venous system without perforating venous imaging. Time-SLIP method was temporally and spatially limited to a potentially extensive venous system.

Discussion

Non-contrast half-Fourier FSE MR angiography provided good visualization of the small and tortuous perforating veins with age-related vasodilatation. Selective depiction of sources of varicose veins is of increasing significance on variceal ablation procedures in our aging population.

References

- 1) Miyazaki M, S. Vivian. Radiology, 248:20-42; 2008
- 2) Edelman RR, Koktzoglou I. Radiology, 250 :236-245; 2009
- 3) Kanazawa H and Miyazaki M, ISMRM 2002, p140

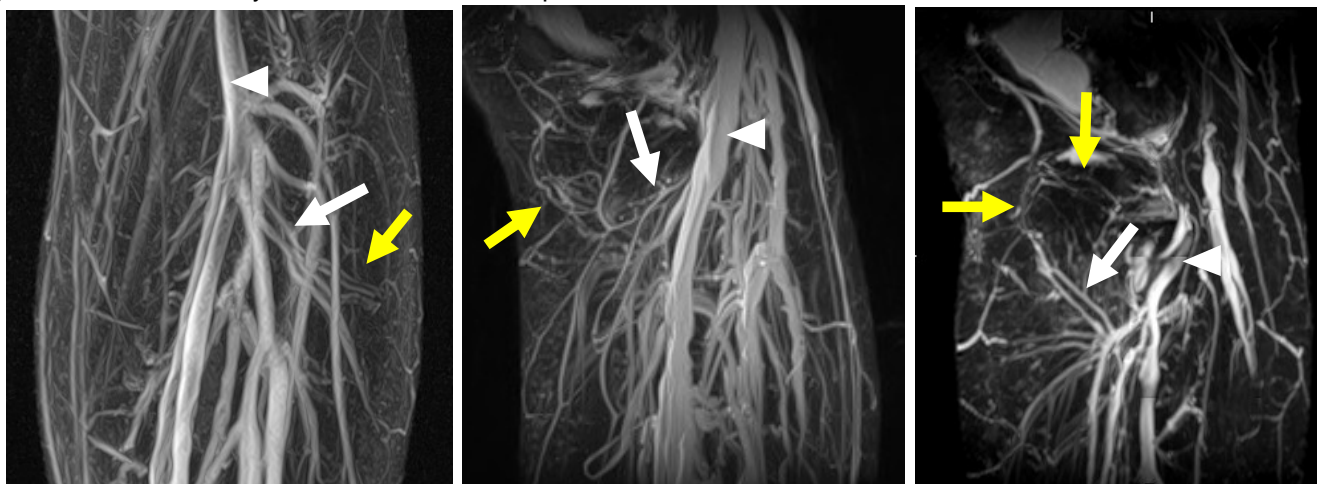


Fig. 1) Non-contrast half-Fourier FSE MR venography of age-related vasodilatation in the upper calf. Partial MIP images in a 28-year-old male on coronal section (a), a 35-year-old female (b) and a 48-year-old female (c) on sagittal section show perforating veins (yellow arrows) which arise from small gastrocnemius branches (arrows) and deep venous system (arrow heads). Note that tortuous perforating veins with age-related vasodilatation increase and orient in the cranial direction with aging.