

Equilibrium-phase thoracic MR angiography with gadofosveset in healthy volunteers: feasibility and minimal practical dose

Charles Y Kim¹, Tobias J Heye¹, Mustafa R Bashir¹, Thomas Gebhard¹, Bjorn I Engstrom¹, and Elmar M Merkle²
¹Radiology, Duke University, Durham, NC, United States, ²Radiology, University of Basel Hospital, Basel, CH-4031, Switzerland

Target Audience: Clinical radiologists who interpret cardiovascular MRI.

Purpose: Minimization of gadolinium dose has been advocated by numerous organizations and societies in patients with renal impairment to avoid NSF. Dose reduction is sometimes performed in patients with borderline renal function. The purpose of this study was to evaluate the feasibility and minimal practical dose of equilibrium-phase MR angiography of the thoracic vasculature using gadofosveset in healthy volunteers.

Methods: This study was approved by our institutional review board. Informed consent was obtained from all subjects. Thirty healthy volunteers were randomized to receive one of three doses of gadofosveset: 0.03, 0.02, or 0.01 mmol/kg. MRA was performed at 3T in the equilibrium phase 5 minutes post-injection. Two blinded radiologists assessed the central veins, the pulmonary arteries, and the thoracic aorta. Qualitative vessel visibility was independently rated for vascular segments on a scale of 0-3. Quantitative signal-to-noise(SNR) and contrast-to-noise(CNR) ratios were calculated.

Results: At a dose of 0.03 and 0.02 mmol/kg, neither reader scored any vessel segments as inadequate. At a dose of 0.01 mmol/kg, 6% of central venous segments, 10% of pulmonary arteries, and 10% of aortic segments were collectively rated as inadequate. While both the SNR and CNR were significantly lower at a dose of 0.01 in all vascular distributions compared to higher doses, the CNR and SNR at doses of 0.02 and 0.03 mmol/kg were similar for the pulmonary arteries and aorta.

Discussion: By virtue of the prolonged intravascular time of gadofosveset, the venous, pulmonary arterial, and aortic vessels were adequately allowing image acquisition in the equilibrium phase with uniform enhancement of all vascular distributions in the body. Using a single equilibrium phase acquisition at a 33% lower dose than the manufacturer recommended dose, vessel enhancement was adequate for visualization of the central veins, pulmonary arteries, and aorta. At a 66% dose reduction, the vast majority of vessels were still adequately visualized.

Conclusion: Equilibrium-phase MR angiography of the thoracic vessels in healthy volunteers resulted in adequate vessel visualization, even when dose reduction was performed. This strategy may be useful for patients with borderline renal function.

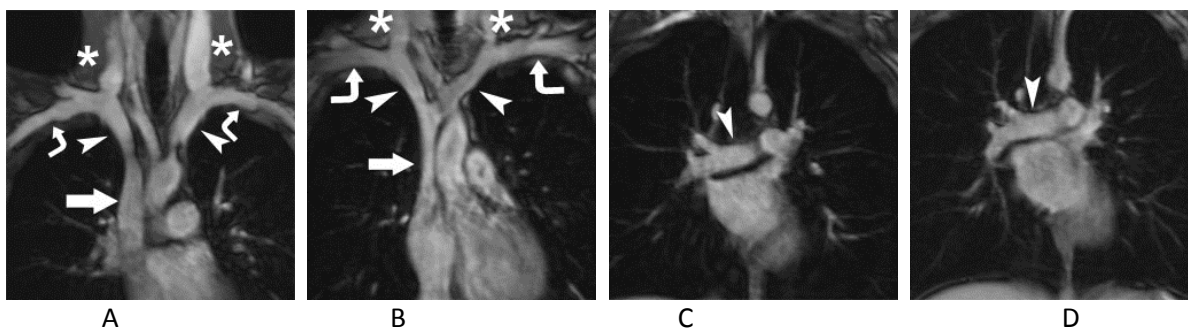


Figure. Coronal MRA with gadofosveset in the equilibrium phase in healthy volunteers at a dose of 0.03 mmol/kg and 0.01 mmol/kg: Image containing central veins at a dose of 0.03(A) and 0.01(B): SVC (block arrow), brachiocephalic veins (arrowheads), subclavian veins (curved arrows), and internal jugular veins (*); Image containing the right main pulmonary artery (arrowhead) at a dose of 0.03(C) and 0.01 (D).