

Role of Intravoxel Incoherent Motion MR Imaging in Evaluating Different Types of Uterine Fibroids in Patient Selection before MR-guided Focused Ultrasound Ablation

Rong Rong¹, Juan Wei², Xuedong Yang¹, Jing Liu¹, Ying Zhu¹, Bilgin Keserci³, and Xiaoying Wang¹

¹Radiology Department, Peking University First Hospital, Beijing, China, ²Philips Research Asia, Shanghai, China, ³Philips Healthcare South Korea, Seoul, Korea

Target Audience: Gynecologist and Radiologists who focus on gynecology MR imaging

Purpose: For MR-guided focused ultrasound ablation, conventionally Funaki classification using T2WI^[1] is used for uterine fibroids classification, which purely depends on T2W images contrast and is not accurate especially in differentiating between type 2 and type 3. In this study, we investigate the value of perfusion fraction and diffusion coefficient derived from different b-values combined DWI MR images to quantize the fibroid vascularity and improve the accuracy of classification for different types of uterine fibroids based on T2WI.

Materials and Method: Subjects: A total of 24 uterine fibroids (diameter: mean, 5.6 cm; range, 3.5–8 cm) in 16 female patients (mean age, 47.3 years) underwent pre-ablation MRI screening. All subjects provided written informed consent. MRI Acquisition: In the screening procedure, subjects were positioned prone, feet first, on the MR table inside the 3T MRI scanner (Achieva TX, Philips Medical Systems, Best, the Netherlands) using a 32-channel phased array coil. Each subject accepted T2WI and intravoxel incoherent motion MR imaging of the axial plan across the uterus. We set different b-values as follows: 0, 25, 50, 75, 100, 150, 200, 500, 800, and 1000 (s/mm²). Data Analysis: Freehand ROIs circumscribing the fibroids were drawn and data were analyzed by using DWI post-processing software performed in a proprietary programming environment (PRIDE; Philips Medical Systems). For low b-value (<200 s/mm²), biexp-ivim model was used and for high b-value (200-1000 s/mm²), Kurtosis model was used to calculate perfusion fraction and diffusion coefficient. Quantitative difference in perfusion fraction and diffusion coefficient was analyzed among different types of fibroids. Analysis of variance was used to do statistical analysis.

Results: On T2WI, out of 24 fibroids, type 1, 2 and 3 fibroids were sixteen, five and three, respectively. For type 1, 2, and 3 fibroids, at low b-value, the diffusion coefficient (D) were 1.16±0.37, 0.88±0.42, 1.62±0.11 (um²/ms) (P<0.05), and perfusion fraction (f) were 0.16±0.087, 0.18±0.091, 0.14±0.025 (P<0.05) (Figure1, 2, 3). For type 1, 2, and 3 fibroids, at high b-value, the diffusion coefficient (D) were 1.09±0.34, 1.29±0.24, 1.59±0.089 (um²/ms) (P<0.05), and perfusion fraction (f) were 0.18±0.092, 0.16±0.099, 0.15±0.016 (P<0.05), and K value were 1.43±1.03, 1.05±0.38, 0.67±0.063 (P<0.05).

Discussion: The results show that type 3 fibroids had obvious high diffusion and low perfusion fraction compared to type 1 and 2 fibroids (D=1.59±0.089 um²/ms, K=0.67±0.063, f=0.14±0.025). And the parameters derived from the low b-value images correlated very well with the biological features of fibroids. Type 3 fibroids are hypervascularity, which are difficult to be treated by focused ultrasound ablation because the blood vessels effectively carry the thermal energy away from the treatment area. Simultaneously hypervascularity and chaotic vasculature status may lead strong diffusion in type 3 fibroids. According to the biexponential ivim model ($f = 1 - \exp[-b_1 \cdot (ADC - D)]$)^[2], high diffusion is related to a relatively low perfusion fraction, which is verified in type 3 fibroids. And in Kurtosis model ($\ln(S(b)/S_0) \approx -f - bD(1 - bDK/6)$)^[3], K value is reversely related to diffusion. Therefore, diffusion and perfusion fraction values derived from multi b DWI images are very useful and more accurate to obviously classify different uterus fibroids, especially between type 2 and 3, which are generally not easy to be defined based on T2W images. **Conclusion:** The combined analysis of perfusion fraction and diffusion coefficient derived from multiple b-values DWI MR

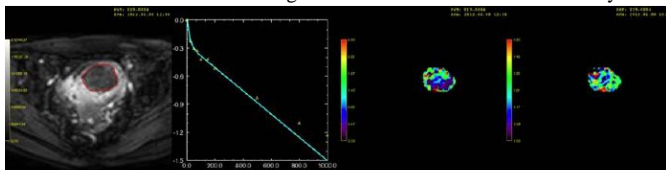


Figure1: Type 1 fibroids biexp-ivim fitting curve, diffusion coefficient and perfusion fraction map.

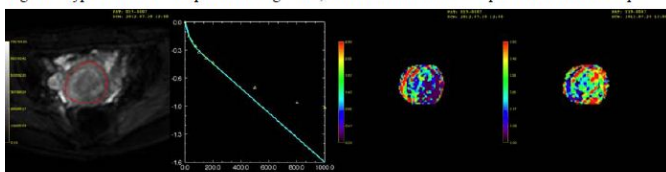


Figure2: Type 2 fibroids biexp-ivim fitting curve, diffusion coefficient and perfusion fraction map.

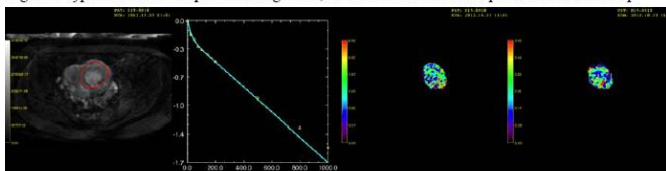


Figure3: Type 3 fibroids biexp-ivim fitting curve, diffusion coefficient and perfusion fraction map.

images quantitatively reflect vascularity (or perfusion) in different types of fibroids and will definitely help to do more accurate classification, especially to differentiate the type 3 fibroids. When this new approach shown in this abstract is combined with T2W based classification, it might greatly improve the accuracy and efficiency of MR screening before MR-guided focused ultrasound ablation.

References: [1] Funaki K, Fukunishi H, Funaki T, et al. Magnetic resonance-guided focused ultrasound surgery for uterine fibroids: relationship between the therapeutic effects and signal intensity of preexisting T2-weighted magnetic resonance images. *Am J Obstet Gynecol.* 2007; 196(2):184.e1-6. [2] Le Bihan D. Diffusion, perfusion and functional MRI. *Neuroimage.* 2012; 62(2):1131-6. [3] De Santis S, Gabrielli A, Palombo M, et al. Non-Gaussian diffusion imaging: a brief practical review. *Magn Reson Imaging.* 2011; 29(10):1410-6.