

Free-Breathing Dynamic Contrast Enhanced Compressed-Sensing Imaging for Reliable Estimation of Liver Perfusion

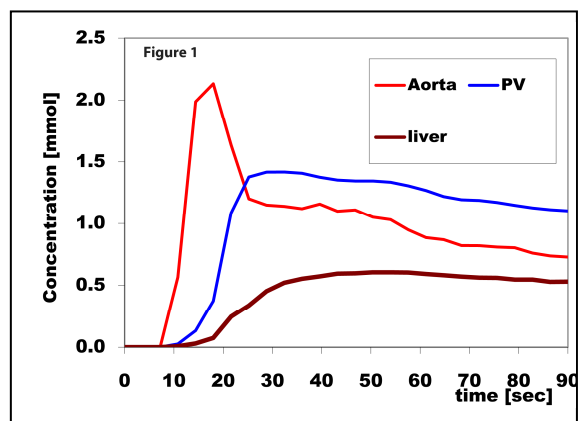
Hersh Chandarana¹, Kai Tobias Block¹, Henry Rusinek¹, Matthew B Greenberg¹, Li Feng¹, Daniel K Sodickson¹, and Ricardo Otazo¹
¹Radiology; Center for Biomedical Imaging, NYU Langone Medical Center, New York, NY, United States

Target Audience: Abdominal Radiologists and scientists interested in dynamic perfusion imaging

Purpose: Dynamic contrast-enhanced (DCE) T1-weighted imaging of the liver with high temporal resolution is a valuable method for measuring perfusional changes in the liver. Several studies have shown utility of perfusion metrics in diagnosis of advanced liver fibrosis and assessment of portal hypertension (1, 2). 3D acquisitions, in comparison to 2D acquisitions, have the advantage of covering the entire liver, which is essential when evaluating liver fibrosis and cirrhosis which has heterogeneous distribution. However, this extended anatomic coverage is at the expense of lower temporal resolution and/or lower in-plane spatial resolution on conventional DCE. One approach for accelerated imaging acquisition is the use of compressed sensing (CS) reconstruction techniques, where temporal correlations in the dynamic imaging data are exploited to reduce k-space sampling necessary to generate an image (3). We have recently developed a novel acquisition and reconstruction method that combines compressed sensing and parallel imaging for golden angle radial sampling called GRASP (Golden-angle Radial Sparse Parallel) imaging (4). We have previously shown the feasibility of DCE GRASP for performing free-breathing high temporal resolution imaging of the liver in healthy subjects (5). The purpose of this prospective study was to compare various perfusion metrics (obtained with dual input single compartment model) in healthy subjects and patients with liver cirrhosis undergoing DCE GRASP imaging.

Methods: In this prospective HIPAA compliant IRB approved study, 6 healthy male subjects and 3 male subjects with liver cirrhosis (proven at anatomic imaging) were imaged at 3 T (MAGNETOM Verio, Siemens AG, Erlangen, Germany). MR acquisition was initiated simultaneously with intravenous injection of 10 cc of gadopentate dimeglumine (Magnevist; Berlex Laboratories, Wayne, NJ) followed by a 20-ml saline flush, both injected at a rate of 2cc/second. A 3D stack-of-stars gradient echo sequence with continuous radial trajectory was used for imaging: slice thickness = 3 mm, voxel size 1.6 x 1.6 x 3 mm, flip angle = 12°, TR/TE = 3.56-3.62 ms/1.51-1.55 ms, 80 slices, BW 590-610 Hz/pix. 600 radial spokes were acquired continuously in 90 seconds. A time-series of images with high temporal resolution were generated by grouping 21 (a Fibonacci number to provide relatively uniform k-space coverage) adjacent spokes as one time point, resulting in a temporal resolution of approximately 3 seconds by technique previously described (4, 5). GRASP reconstruction was performed with a standalone implementation written in C++.

Image Analysis: A reader blinded to the patient diagnosis placed small (approximately 10 to 20 mm) regions-of-interest (ROI) in the aorta, main portal vein, and the right and left lobe of the liver parenchyma at the level of the porta-hepatis to measure signal-intensity. No image registration was necessary. The ROIs were propagated to the dynamic series to generate signal-intensity time curves (Figure 1). These were converted to gadolinium concentration-time curve (2). Dual input single compartment model was employed (6) to generate various perfusion metrics which were compared between the healthy and cirrhotic subjects.



Results and Discussion:

There was significant higher apparent arterial perfusion (Fa), arterial fraction (%ART), mean transit time (MTT), and distribution volume (DV) in cirrhotics compared to the healthy subjects (Table 1). Although apparent portal perfusion was decreased in the cirrhotics compared to healthy subjects, this did not reach statistical significance. These findings are concordant with previous studies that utilized Cartesian acquisition schemes.

Table 1	ART%	DV%	MTT (sec)	Fa (ml/100g/min)	Fp(ml/100g/min)
Healthy	13.5 ± 1.9	23.0 ± 8.6	11.7 ± 4.0	14.3 ± 6.0	105.3 ± 25.5
Cirrhotics	37.0 ± 9.6	52.3 ± 14.6	25.3 ± 12.3	46.7 ± 12.5	79.7 ± 19.6
P value	<0.05	<0.05	0.03	<0.05	0.17

Conclusions: Free-breathing GRASP dynamic perfusion imaging of the liver with pharmacokinetic modeling can help discriminate cirrhotics from healthy subjects with results concordant to that obtained with published Cartesian acquisition scheme. Advantages over Cartesian scheme include whole liver coverage with higher spatial and temporal resolution, motion robustness eliminating need for labor intensive registration, and images can be reconstructed from the data used for clinical exam eliminating need for additional contrast dose or acquisition time. Future work will focus on discriminating patients with different degree of fibrosis.

Grant Sponsor: NIHR01-EB000447

References: 1. Annet I et al. Radiology 2003. 2. Taouli B et al. Radiology 2008. 3. Lustig et al, MRM 2007 4. Chandarana et al, Invest Radiol, in press, 2013. 5. Chandarana et al. ISMRM 2012. 6. Materne R et al. Clinical Science 2000.