

7T MR spectroscopic imaging in localization of surgically treated epilepsy

Jullie W Pan¹, R Bradley Duckrow¹, Jason Gerrard², Caroline Ong¹, Lawrence Hirsch³, Stanley Resor, Jr⁴, Ognen Petroff³, Susan S Spencer³, Hoby P Hetherington², and Dennis D Spencer²

¹Yale University School of Medicine, New Haven, CT, United States, ²Neurosurgery, Yale University School of Medicine, New Haven, CT, United States, ³Neurology, Yale University School of Medicine, New Haven, CT, United States, ⁴Neurology, Columbia University School of Medicine, New York, NY, United States

Introduction: For the neurosurgical evaluation of intractable epilepsy, localization of seizure onset results from an analysis of imaging, semiology and EEG. The challenges of this process are known, given the varying clinical expression of different brain regions and the strong possibility for rapid seizure propagation. MRSI has been suggested to be informative for localization, premised on NAA's role in neuronal mitochondrial function. As suggested by Connett 1988 (1), the normalization of bioenergetic parameters by total creatine is highly informative over a cross section of species and within a given tissue type; thus the parameter NA/Cr is commonly used to identify regions of energetic and neuronal dysfunction. We describe the use of ultra-high field (7T) NA/Cr MRSI towards seizure localization in n=25 surgically treated epilepsy patients, evaluating the relationship between outcome with concordance of MRSI abnormality and surgical resection.

Methods: Imaging: We used a head only Agilent Varian 7T MR system with 1st-3rd order shims and an 8 element transceiver array for all studies. Because of the need for excellent Bo homogeneity over large regions of the brain sufficient for spectroscopic imaging, a RRI high (4th) degree shim insert coil was additionally used in conjunction with map based non-iterative shimming methods. The transceiver array was used with RF shimming to optimize multiple spatially distinct RF distributions to achieve 1kHz B1 transmission over large volumes sufficient for spectroscopic spin echo imaging and outer volume suppression. Spectroscopic localization was achieved with a combination of gradient based slice-selective excitation (10mm thick slices) and RF shimming based outer volume suppression as previously described. All MRSI studies were acquired as Hahn spin echoes with TR/TE 1.5s/40ms with rectangular phase encoding, total duration of any study ~80min. **Clinical:** n=25 patients were recruited by the Yale and Columbia epilepsy centers. Patients were included if a surgical resection was performed and if the pre-operative MRSI data overlapped with the surgical resection. Three levels of concordance were used: Class 1: the surgical resection wholly included the region of NA/Cr abnormality; Class 2: the surgical resection partly included the region of NA/Cr abnormality; Class 3: the surgical resection did not show any NA/Cr abnormality. Outcome was classified using the ILAE scale with two outcomes I-III (good) and IV-VI (poor). The data were evaluated using a 3x2 contingency table, comparing the concordance Class with outcome.

Results: In n=9/25 patients, there was MR-detected asymmetric hippocampal atrophy; n=10/25 had other clinical MRI-detectable abnormalities such as periventricular heterotopia, gray-white blurring. n=6/25 had a negative clinical MRI. A total of n=16 patients underwent intracranial monitoring for seizure localization. Table 1 shows the resulting contingencies, using letters A-F to describe the 6 possible groups. A Fisher's exact test shows that the concordance between MRSI/surgical resection was significantly related to good outcome, p<0.001. Fig. 1 shows data from a MRI-negative patient in group F, showing several regions of abnormality.

Table 1: 3x2 contingency on Concordance and Outcome	Outcome I-III (good)	Outcome IV-VI (poor)
1 Concordant: surgical resection completely includes NA/Cr abnormality	A: 14	D: 0
2 Partial concordance: surgical resection partly includes NA/Cr abnormality	B: 2	E: 4
3 Discordant: surgical resection does not include any NA/Cr abnormality	C: 1	F: 4

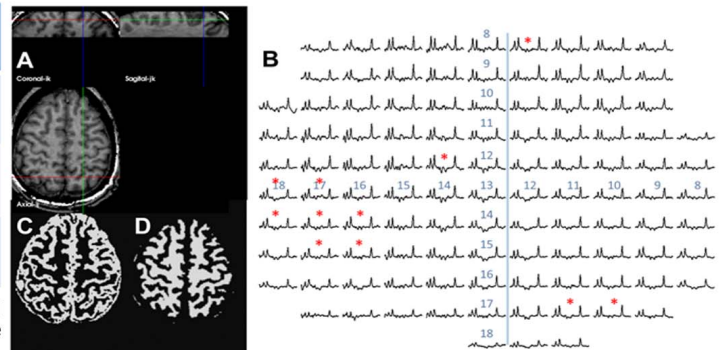


Fig. 1 (right) Data from a patient from group F showing structural, spectra and tissue segmented data. The asterisks identify abnormal voxels of NA/Cr.

Conclusions: The simplest explanation for the significant correlation is that epileptogenic tissue is characterized by metabolic dysfunction and mitochondrial injury. Notably, of the n=8 poor outcome patients (contingency groups E and F), MRSI identified other regions of NA/Cr abnormalities in at least 7. This may reflect that abnormalities in NA/Cr can occur without being directly at the site of seizure onset, may reflect the presence of a seizure or epilepsy network, or given the complex nature of this patient group, there may be multiple loci of seizure onset. Nonetheless, given the significant relationship between MRSI/resection and outcome, it is clear that for the majority of our patients, finding and resecting a region of abnormal NA/Cr characterizes better patient outcome than resecting a metabolically normal region.

The present data also show that the volume of metabolic dysfunction is variable and can be reasonably small with a resulting need for excellent spectral quality and high spatial resolution. It should be noted that while the Bo developments have been critical for 7T work, they have immediate relevance for 3T or 4T, which is known to suffer from similar but milder problems especially in lower brain regions. With continuing studies of this kind, we anticipate that seizure localization can be improved, that better definition of the metabolic networks in epilepsy can be achieved, which may hopefully improve outcomes from surgery.

Refs: 1 Connett 1988 Am J Physiol 254(6): R949