

# Detecting and characterizing therapeutic response to radio- & chemotherapies with hyperpolarized [1-<sup>13</sup>C] pyruvate in rat glioma model

Heeseung Lim<sup>1</sup>, Kundan Thind<sup>1</sup>, Timothy Pok Chi Yeung<sup>1,2</sup>, Francisco M Martinez-Santesteban<sup>1</sup>, and Timothy J Scholl<sup>1,3</sup>

<sup>1</sup>Medical Biophysics, Western University, London, Ontario, Canada, <sup>2</sup>London Regional Cancer Program, LHSC, London, Ontario, Canada, <sup>3</sup>Imaging Research Laboratories, Robarts Research Institute, Western University, London, Ontario, Canada

## Target audience

MRI, Hyperpolarized <sup>13</sup>C, Molecular imaging, Small animal imaging, Brain tumor (Glioblastoma Multiforme), Response to therapy; Radiotherapy, Chemotherapy

**Purpose** A primary brain tumor is one of the most difficult tumors to treat. The most common brain tumor, Glioblastoma Multiforme (GBM) is a very aggressive primary tumor with poor long-term patient outcomes regardless of therapy<sup>1</sup>. Furthermore the current gold standard of diagnosis requires invasive stereotactic biopsy or craniotomy<sup>1</sup>. Emerging techniques such as hyperpolarized <sup>13</sup>C magnetic resonance (MR) imaging and spectroscopy use <sup>13</sup>C-enriched organic substrates as molecular imaging probes to observe *in vivo* real time metabolism. Based on the Warburg principle, many tumors exhibit enhanced lactic acid fermentation over oxidation of pyruvate<sup>2</sup>. Imaging probes such as hyperpolarized <sup>13</sup>C-pyruvate facilitate detection of metabolic changes in tumors, which can be monitored longitudinally and correlated with tumor response to different or combined therapies.

**Methods** A total of six Wistar rats were used (to date) in this study. All rats were implanted with approximately one million C6 GBM cells using a stereotactical frame. Ten days after the surgery, 4 rats were treated with radiotherapy and 2 rats received chemotherapy. Radiotherapy rats received a total of 20 Gy localized dose in 2 fractions separated by a day. Chemotherapy rats received a Temozolomide dose of 7.5mg/kg/day over 5 days consecutive days. Rats were imaged with <sup>1</sup>H MRI and hyperpolarized <sup>13</sup>C at days 7, 12, 14, 18, 21 and 24 after the surgery. A specially constructed switch-tuned <sup>13</sup>C - <sup>1</sup>H radiofrequency coil was used to detect both proton and carbon signals of the rodent brain with high SNR<sup>3</sup>. Each imaging session included T1- and T2-weighted proton imaging of the brain and hyperpolarized <sup>13</sup>C 2D spectroscopy. Axial and coronal T2-weighted proton images were acquired using a fast-spin echo sequence with a 80-mm by 80-mm field of view, 0.3-mm isotropic resolution, 3-mm slide thickness, TR = 4000ms, TE = 85ms, 16-echo train and 9 averages. 80-mM-buffered <sup>13</sup>C-enriched pyruvic acid solution was hyperpolarized using the HyperSense (Oxford Instruments) dynamic nuclear polarizer and given as a tail vein bolus injection. <sup>13</sup>C spectra (axial plane, 12 by 12 spectral imaging matrix, TR = 80ms, BW = 5kHz, 2048pts) were recorded using a free-induction decay chemical-shift imaging pulse sequence encompassing the rat head with a 60-mm by 60-mm field of view, slide thickness ≈ tumor size. All animal procedures were approved by the University Council on Animal Care, Animal Use Subcommittee at Western University.

**Results** Prior to therapy, the typical Lactate/Pyruvate ratio (Lac/Pyr) of a tumor voxel is greater than that in a healthy brain voxel as shown in Figure 1. Longitudinal changes of Lac/Pyr in healthy brain voxels and tumor voxels for each therapy is shown in Figure 2. At day 7, prior to treatment Lac/Pyr is the same for all tumor voxels. This was also observed in healthy brain voxels. Both radiotherapy and chemotherapy rats showed changes in Lac/Pyr in tumors by day 12 (3 days after therapy). Eventually, Lac/Pyr in tumors decreased to that of healthy brain tissue around day 18. Chemotherapy rats did not survive beyond day 18 due to dehydration and weight loss. Radiotherapy rats survived beyond day 24 and showed a slight increase in Lac/Pyr in tumor voxels. The significance of this change is not known at this juncture due to limit sample size.

**Discussion** The similar Lac/Pyr in healthy & diseased brain voxels suggests high reproducibility of the tumor model. Radiotherapy rats showed a faster decrease in Lac/Pyr, which would likely explain increased longevity compared with chemotherapy rats. However, radiotherapy rats may have also shown reoccurrence of the tumor with an increase in Lac/Pyr after day 18. Chemotherapy potentially produced a larger reduction in Lac/Pyr than radiotherapy but it also elicited a slower response to the therapy and is likely the cause of reduced survivability. These metabolic changes were readily detected between frequent imaging sessions. However, with T2-weighted proton imaging, changes in contrast or size of tumor were not remarkable. Only after a week post therapy, some slight changes were noted but the sensitivity of detecting tumor response to the therapy is far superior for hyperpolarized <sup>13</sup>C imaging than conventional proton imaging.

**Conclusion** Conventional MRI/CT provides little information about tumor response to therapy and biopsy is very invasive procedure. The use of hyperpolarized <sup>13</sup>C pyruvate to probe real time tumor metabolism can provide *longitudinal non-invasive biomarkers* for therapeutic response to radio- and chemotherapy. This study has provided some evidence of detection of early metabolic change as a result of tumor response to radiotherapy and chemotherapy. Furthermore, a difference in therapeutic response is well-observed for these two treatments. This study will proceed to include more animals with a combination of therapies with the aim to provide data to guide clinical practice.

## References

1. R Stupp et al. Effects of radiotherapy with concomitant and adjuvant temozolomide versus radiotherapy alone on survival in glioblastoma in a randomised phase III study: 5-year analysis of the EORTC-NCIC trial. *The Lancet oncology* 2009; 10; 459-466
2. J.-w. a. Kim et al. Cancer's molecular sweet tooth and the Warburg effect. *Cancer research* 2006; 66; 8927-8930
3. Heeseung Lim et al. Switch-Tuned Dual-Frequency Birdcage RF coil for <sup>13</sup>C and <sup>1</sup>H imaging. *ISMRM 20<sup>th</sup>* 2012;

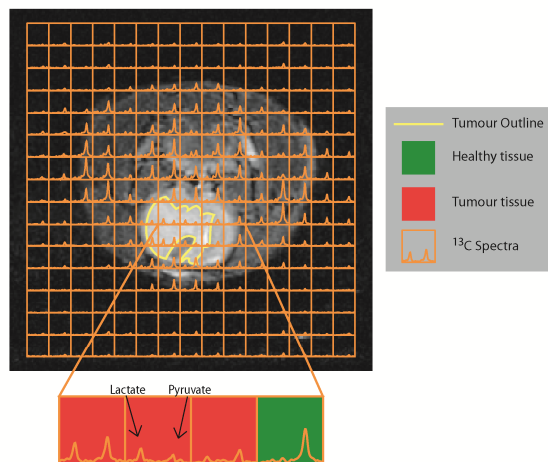


Figure 1: 2D <sup>13</sup>C spectral overlay on a T2-weighted proton image of a rodent brain. Tumor voxels show greater lactate/pyruvate ratio than voxels of healthy brain tissue.

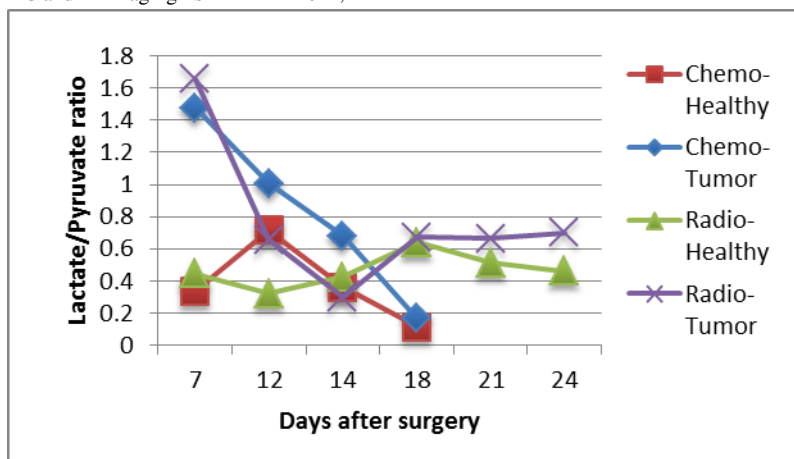


Figure 2: Longitudinal changes in the lactate/pyruvate ratio of healthy brain voxels and brain tumor voxels after chemotherapy and radiotherapy. Each point represents the average of voxels in healthy or tumorous brain tissue corresponding to each therapy.