

Value of wholebody ¹⁸F-FDG PET/MRI in the diagnosis liver metastases in comparison to PET/CT

Karsten Beiderwellen¹, Benedikt Gomez², Verena Hartung-Knemeyer², Christian Buchbender³, Felix Nensa¹, Hilmar Kuehl¹, Andreas Bockisch², and Thomas C. Lauenstein¹

¹Department of Diagnostic and Interventional Radiology and Neuroradiology, University Hospital Essen, Essen, Germany, ²Clinic for Nuclear Medicine, University Hospital Essen, Essen, Germany, ³Department of Diagnostic and Interventional Radiology, University Hospital Dusseldorf, Dusseldorf, Germany

Target audience

The presentation is addressed to physicians and physicists with special interest in oncologic molecular imaging.

Purpose

Previous studies on retrospective PET/MRI fusion described superior results for lesion detection and characterization in comparison to PET/CT^{1,2}. In clinical practice, retrospective fusion is often inapplicable due to its time consuming nature and differing patient positions in PET/CT and MRI. The first integrated PET/MRI scanners have recently been put into operation and allow for a co-registration of PET and MRI. Depending on the scanner concept the acquisition of PET and MRI is either simultaneous or sequential. The purpose of this study was to evaluate the potential of simultaneously acquired wholebody PET/MRI with ¹⁸F-FDG in the diagnosis of liver metastases in comparison to PET/CT.

Methods

71 patients with histopathologically confirmed solid tumors received in a first step a whole body PET/CT in full dose-technique (Biograph mCT 128, Siemens Healthcare). Primary tumors included: malignant melanoma (n = 25), breast cancer (n = 10), lung cancer (n = 9), adenoid-cystic carcinoma (n = 8), colorectal cancer (n = 4) and others (n = 15). All patients subsequently underwent a wholebody PET/MRI (Biograph mMR, Siemens Healthcare). The PET/MRI protocol comprised the following sequences: 1) T1w FLASH, 2) T2w HASTE, 3) DWI, 4) gadolinium enhanced T1w 2D FLASH fs. The resulting datasets (PET/CT, PET/MRI) were rated separately by two readers. The criteria comprised scores for lesion detectability (0: not visible, 1: low contrast, 2: intermediate contrast, 3: high contrast) and diagnostic confidence (1 = certainly benign; 2: rather benign; 3: indeterminate; 4: rather malignant; 5: certainly malignant). All available data (history, historical exams, PET/CT; PET/MRT) and a clinical follow-up (mean: 98 days) served as standard of reference. Statistical analysis was performed using a non-parametric test (Wilcoxon signed-rank test).

Results

In 37 of the 71 patients focal liver lesions were found. According to the reference standard liver metastases were present in 10 patients. A total of 98 liver lesions were described (73 benign; 25 malignant). All malignant liver lesions were correctly identified based on PET/CT or PET/MRI. Significantly higher scores for lesion delineation were found based on PET/MRI, both for malignant (PET/CT: 2.68 [95% CI: 2.49 to 2.87]; PET/MRI 2.96 [95% CI: 2.88 to 3.04]; p < 0.008) and for benign lesions (PET/CT: 2.28 [95% CI: 2.02 to 2.48]; PET/MRT 2.89 [95% CI 2.82 to 2.96]; p < 0.0001). Diagnostic confidence was significantly higher with PET/MRI for benign lesions (PET/CT: 1.81 [95% CI: 1.63 to 1.99]; PET/MRT: 1.19 [95% CI: 1.08 to 1.3]; p < 0.0001) as well as for malignant lesions (PET/CT: 4.44 [95% CI: 4.24 to 4.64], PET/MRI: 4.84[95% CI: 4.69 to 4.99]; p < 0.002).

Discussion

This is the first work demonstrating the potential of integrated PET/MRI in the diagnosis of liver metastases. Due to the high soft tissue contrast of MRI significantly higher scores for lesion conspicuity and diagnostic confidence were found. However, no additional malignant lesions were seen based on PET/MRI. Further studies using PET/MRI-protocols comprising a dedicated, multi-phase contrast enhanced Liver protocol will be focus of future studies.

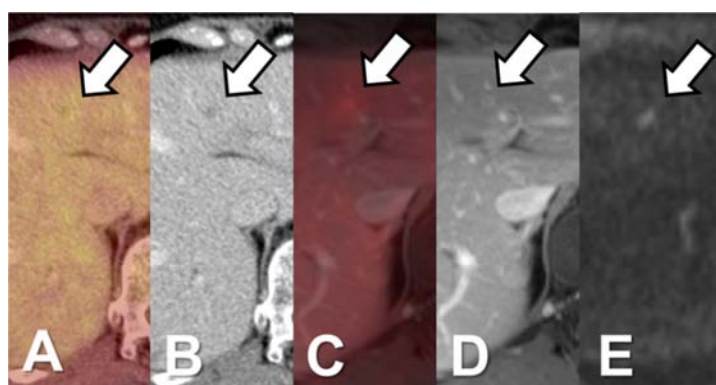


Figure 1: Patient with liver metastasis in segment IVa. PET/CT (A+B) shows small, hypodense liver lesion without elevated tracer uptake. In PET/MRI (C-E) the lesion shows a ring enhancement in T1 FLASH 2D (D) and diffusion restriction in DWI (E; B = 1000) as reliable signs of malignancy.

Conclusion

Integrated PET/MRI utilizing ¹⁸F-FDG improves lesion delineation and diagnostic confidence for the assessment of liver lesions compared to PET/CT.

References

1. Donati OF, Hany TF, Reiner CS, et al. Value of retrospective fusion of PET and MR images in detection of hepatic metastases: comparison with ¹⁸F-FDG PET/CT and Gd-EOB-DTPA-enhanced MRI. *J Nucl Med.* 2010 May;51(5):692-9. Epub 2010 Apr 15.
2. Tatsumi M, Isohashi K, Onishi H, et al. ¹⁸F-FDG PET/MRI fusion in characterizing pancreatic tumors: comparison to PET/CT. *Int J Clin Oncol.* 2011 Aug;16(4):408-15. Epub 2011 Feb 24.