

RETROSPECTIVE SELF-GATED MRI OF THE TMJ DYNAMICS DURING MASTICATION

Stefan Wundrak^{1,2}, Jan Paul¹, Johannes Ulrici², Erich Hell², and Volker Rasche¹

¹Klinik für Innere Medizin II, Ulm University, Ulm, Germany, ²Sirona Dental Systems, Bensheim, Germany

Purpose Assessment of the masticatory motion of the temporomandibular joint (TMJ) is of interest for a variety of pathologies, e.g. the abnormal motion of the articular disc. Current approaches for measuring mastication include tracking through external devices [1] and the static or pseudo-dynamic visualization through MRI [2]. However, the dynamic visualization of the TMJ under realistic mastication is still limited by the poor spatial-temporal resolution [3]. Recently, we have shown the feasibility of retrospective gated reconstruction using a device that tracks the angular position of the mandible [4]. In this contribution we introduce a retrospective self-gated reconstruction method for the imaging of the TMJ dynamics.

Methods

Acquisition: The acquisition was performed using a radial trajectory with a golden angle acquisition scheme [6] to avoid gaps in the gated data set (Fig. 2). Two healthy volunteers were instructed to masticate continuously and as uniformly as possible. Acquisition parameters were: 3T, in-phase steady-state gradient echo, a two channel carotid prototype coil, TE/TR = 2.3/4.6ms, flip angle = 20°, pixel bandwidth of 949 Hz, and spatial resolution of 0.75x0.75x5mm³. The data was acquired over a period of 47s at a frequency of 15-25 cycles per minute.

Self-Gating: A single 1D Fourier transformed radial k-space profile equals a projection of the acquired slice. For a static object the integral over the projection should be constant over time and independent of the acquisition angle. For a cyclic moving object the variation of the integral is supposed to correlate with the moving state of the object [5]. Band-pass filtering with the expected mastication frequency of 0.15 to 3 Hz eliminates any radial dependent variations introduced by non-idealities and leads to the kymogram as shown in Figure 1. Finally, the radial profiles are re-sorted by its kymogram value.

Reconstruction: A gridding reconstruction with 340 profiles per image was used to reconstruct a movie of 40 time frames from the self-gated profiles. For comparison, a real-time movie with a comparable temporal resolution has been reconstructed without gating from the unsorted profiles using an intermediately regularized sparse SENSE reconstruction [7] with 34 profiles per image and temporal total variation regularization.

Results Figure 3 shows temporal snapshots of the reconstructed TMJ mastication cycle. Despite the continuous motion of the TMJ, the mandible, the fossa mandibularis, the involved musculature, and the ligamentous apparatus is clearly visible and the position of the discus articularis can be estimated. The self-gating signal clearly correlated with the reference signal measured by the previously introduced tracking device [4] (Fig.1). The golden angle reduced the feasible sliding window width by a factor of two (Fig.2). In comparison with the real-time reconstruction the self-gated reconstruction showed a significantly improved spatial resolution (Fig.4).

Discussion The application of a self-gated retrospective reconstruction of the TMJ dynamics appears feasible. While previous real-time acquisition of the TMJ reached a temporal resolution of 1-3 Hz [3] the proposed technique showed a temporal resolution of about 10 Hz and allowed for the first time the imaging of the TMJ dynamics under continuous mastication.

References [1] Tymofiyeva O, et al. An. of Anat. 2007;189:356-361. [2] Thomas X, et al. Radiogr 2006; 26:765-781. [3] Zhang S, et al. OMIJ 2011; 5:1-7. [4] Kammer, et al. ISMRM 2012. [5] Larson A, et al. MRM 2008; 51:93-102. [6] Winkelmann S, et al. IEEE Trans Med Imag 2007;26:68-76. [7] Wundrak S, et al., Proc. ESMRMB, 2012.

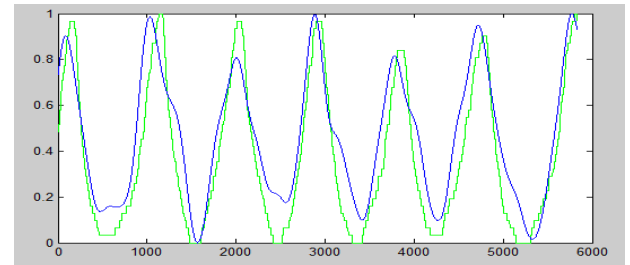


Figure 1 Normalized and band-pass filtered integral of the acquired profiles (blue) and the reference data measured by a tracking device (green).

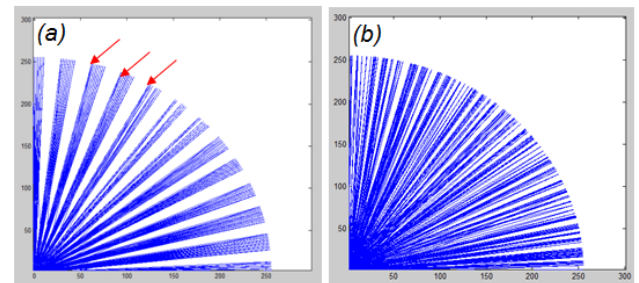


Figure 2 The golden angle acquisition scheme (b) ensures evenly distributed k-space profiles, compared to a successive profile order shown in image (a).

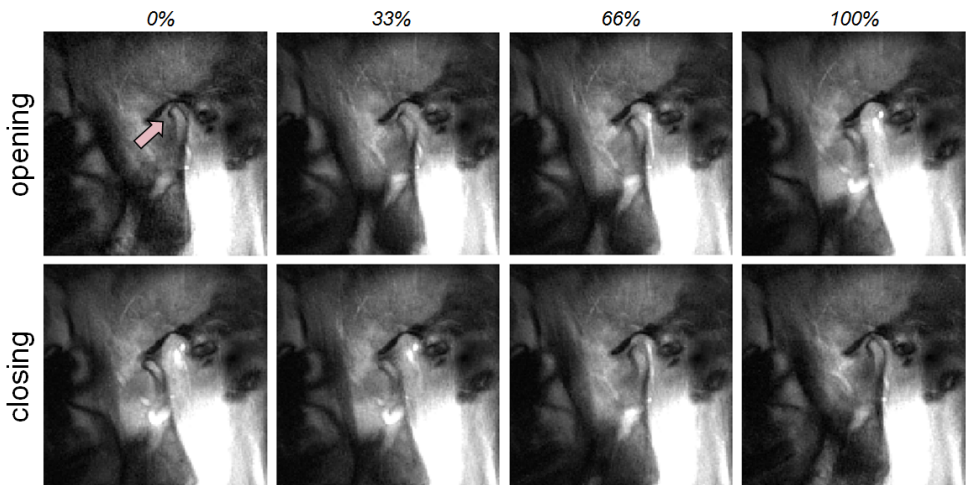


Figure 3 Temporal snapshots of the TMJ dynamics during the mastication cycle reconstructed retrospectively from data acquired continuously during mastication at 0%, 33%, 66% and 100% of the opening / closing phase.

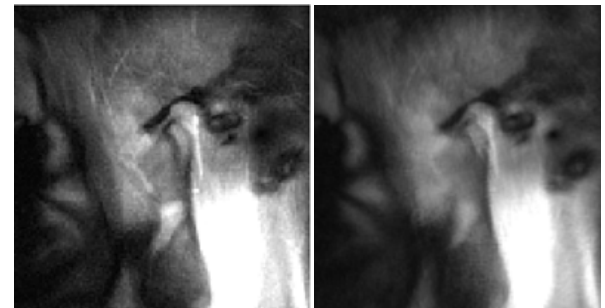


Figure 4 Image showing the rapidly moving condyle, reconstructed with self-gated reconstruction (left) and the real-time reconstruction without gating using 34 profiles per image (right).