

## Effects of ascent to High Altitude: A T2 Relaxometry study on Rat Brain

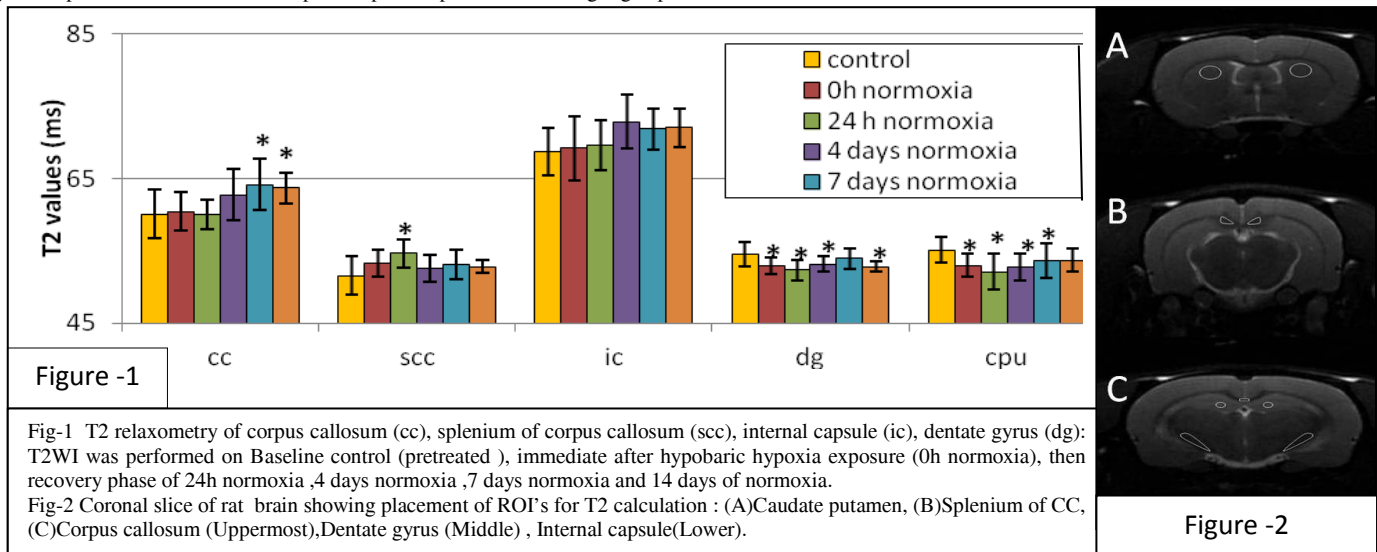
Sunil Koundal<sup>1</sup>, Sonia Gandhi<sup>1</sup>, Tanzeer Kaur<sup>2</sup>, Subash Khushu<sup>1</sup>, and Rajendra P Tripathi<sup>1</sup>

<sup>1</sup>NMR Research Centre, Institute of Nuclear Medicine and Allied Sciences (INMAS), Delhi, India, <sup>2</sup>Department of Biophysics, Panjab University, Chandigarh, Panjab, India

**Introduction:** At high altitude, low air pressure leads to decreased partial pressure of oxygen. Ascent to high altitudes affects human health adversely, due to low oxygen availability to their lungs and all vital organs. Under these hypobaric hypoxia conditions, brain is most adversely affected<sup>1</sup>. Mountain trekkers and army troops working at high altitude are more vulnerable to High altitude sickness. Even among tourists visiting moderate altitudes, headache and reduced mental abilities are being observed. Hence, It is of utmost importance to study Brain areas being affected and related health problems under controlled climatic conditions so that the health issues are addressed properly. MRI can be a good non-invasive tool to study effects of hypobaric hypoxia in rat brain using 7T MRI scanner. T2 weighted imaging may help in analyzing change in brain parenchyma. Our studies on rat model will prove beneficial in understanding the mechanism of disease progression and risk assessment.

**Objective:** To study temporal changes in Rat Brain after exposure to acute hypobaric hypoxia followed by normobaric normoxia using T2WI at 7Tesla.

**Materials and method:** Six SD male rats 11-12 weeks old were exposed to hypobaric hypoxia of 22,000 feet in climatic chamber for 48 hours with temperature and humidity regulated at 25±1°C & 55±1% respectively. T2 weighted imaging [(MSME-T2) TR=3418ms, TE(16)=13-208ms, Slice Thickness /Int.slice dis.=1mm/1mm, Avg=1, Slices=15, FOV=4cm] of rat brain was carried out before (control) and after (0 h) hypobaric hypoxia of 48 hours. Recovery phase was also seen after 24h, 4 days, 7days and 14 days of normobaric normoxia post high altitude stress. Bruker's Paravision v5.1 software was used for T2 weighted mapping of rat brain. ROI's were place over various brain region on coronal slices of rat brain.(Fig-2). T2 value changes in response to hypobaric hypoxia in brain regions were plotted against time and expressed as means ± SD at each time point. Changes in T2rt between various time points were compared by one-way repeated-measures ANOVA followed by an all-pairwise Bonferroni's multiple comparison post hoc test using Sigmaplot.



**Results:** Comparison between various time point groups with pretreated controls showed significant increased T2rt in CC after 7 days and 14 days of normoxia after post high altitude exposure. SCC showed significant increase in T2rt after 24hrs exposure to high altitude stress. T2rt values for IC region also showed increasing trend but the changes were not significant upto 0.05 level. Decreasing trend in T2rt was seen for the grey matter regions. Significant decrease in T2rt values for DG region immediately after hypobaric hypoxic exposure (0 h) were seen which showed a further decrease after 24 h, 4 days, 7 days and 14 days of normoxia. CPU also showed decrease in T2rt immediately after hypobaric hypoxia & a further decrease in T2rt after 24 h, 4 days and 7 days of normoxia.

**Discussion:** Our results shows increase in T2rt in white matter (CC, SCC, IC), which indicates perturbations after high altitude hypoxia at micro-structural level. This is in accordance with previous reports on human<sup>2</sup>. This increase in T2rt suggests an occurrence of edema in these white matter fibres. Decreased in T2rt of grey matter (DG and CPU) may be attributed to iron deposition. Iron deposition in brain parenchyma leads to T2 shortening effect, which is more pronounced at higher field strength of 7T. Frequent iron deposition has been reported in many brain disorders like Alzheimer's disease<sup>3</sup>, Parkinson disease<sup>4</sup>, amyotrophic lateral sclerosis<sup>5</sup> and other abnormal conditions. Iron may play an important role in neurotransmitter metabolism<sup>6</sup> and iron deposition indicates altered neurotransmitter metabolism.

**Conclusion:** T2 MR relaxometry is a powerful tool to give an insight of Hypobaric hypoxia induced changes in brain areas. The results of this work show significant increase in T2 values in rat brain white matter regions and decrease in grey matter on exposure to hypobaric hypoxia, indicating changes in tissue architecture at micro level & possibly an neuronal dysfunction and neurotransmitter metabolism.

### References:

- 1-Wilson MH, et al. Lancet Neurol. 2009. 8:175-191
- 2- Kallenberg, K., et al. J. Cerebr. Blood F. Met. 2007. 27: 1064-71.
- 3 -Brar S, et al Arch Neurol. 2009 . 66(3) : 371-4
- 4 -Antonini A, et al: Neurology1993,43(4):697-700.
- 5 - Oba H, Araki T, Ohtomo K, et al.Radiology1993. 189:843- 846
- 6 - Morris CM, et al. Brain. Acta Anat1992. 143 :14-18