

Cerebral Blood Flow Changes in Glioblastoma Multiforme Patients Undergoing Bevacizumab Treatment Are Seen in Both Tumor and Normal Brain.

Jalal B. Andre¹, Seema Nagpal², Daniel S. Hippe¹, Heiko Schmiedeskamp³, Roland Bammer³, Reena Thomas², Matus Straka³, Lawrence Recht², and Greg Zaharchuk³
¹Radiology, University of Washington, Seattle, Washington, United States, ²Neuro-oncology, Stanford University, Stanford, California, United States, ³Radiology, Stanford University, Stanford, California, United States

Target audience: Neuroradiologists and neurooncologists

Purpose: Bevacizumab (Bev) has been increasingly used for the treatment (tx) of recurrent glioblastoma multiforme (GBM), with reported prolongation of life expectancy via the proposed mechanism of vascular endothelial growth factor receptor-A antagonism. While the intratumoral effects of Bev have been well documented, and are purportedly related to alteration in tumor vascularity, the effects that Bev may exert on overall CBF have not been clearly evaluated. We examine the effects that Bev administration exerts on CBF contralateral to the tumor in patients with recurrent GBM.

Materials & Methods: 19 post-chemoradiation patients with histologically confirmed GBM were treated with Bev and underwent routine tumor imaging at 1.5T and 3T, following informed consent. Pseudocontinuous arterial spin labeling (pCASL) imaging without vessel suppression was serially performed in 18 of these patients using a 3D background-suppressed fast-spin-echo stack-of-spirals readout module with 8 in-plane spiral interleaves. A labeling period of 1500 msec and a post-label delay of 2000 msec were employed, with the labeling plane at the level of the foramen magnum, and in-plane and through-plane resolution of 3 and 4 mm, respectively. CBF quantification (in mL/100g/min) was performed as previously described using an automated script.¹ ROIs were drawn on pCASL images over tumor regions, symmetrically in the contralateral normal appearing white matter/tissue, and the contralateral middle cerebral artery (MCA) territory on an imaging slice 40 mm below the vertex. Changes in CBF from each side within the period before and after Bev administration, and differences between sides for these periods, were evaluated using paired t-tests in 8 patients who underwent pCASL imaging during both periods. A linear-mixed model statistical approach with CBF (GBM or contralateral MCA) as the dependent variable and an indicator for Bev tx period as the independent variable, was also employed in order to utilize all 18 patients, including those with pCASL imaging done in only during one period. To account for any correlation between repeated CBF measurements on the same patient, a random intercept was included and the residual covariance was modeled as a first-order moving average process.² The non-parametric bootstrap was applied to assess the difference in change in CBF between the GBM and contralateral sides.³

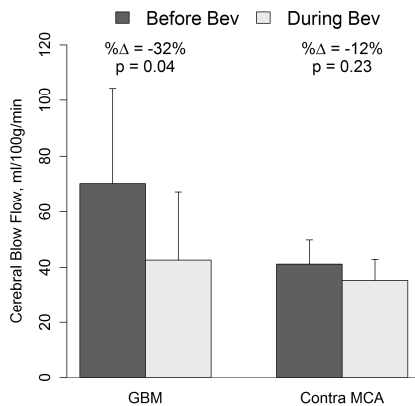


Fig. 1 – Paired t-test results of mean CBF of GBM and contra(lateral) MCA (8 patients).

Results: 63 pCASL studies were serially performed in 18 patients receiving Bev during their GBM treatment. pCASL was performed only before and during Bev tx in 8 patients, only during Bev tx in 6 patients, only during and after Bev tx in 3 patients, and only before Bev tx in 1 patient. Initial chemoradiation was performed in all patients, and most patients underwent chemotherapy (most frequently TMZ and/or CCNU, but also included verubulin, irinotecan, erlotinib, carboplatin, Medi-575, BCNU, or NKTR-102) prior to, or concurrent with Bev treatment. In some, radiation therapy was performed in conjunction with TMZ. Using paired t-tests in 8 patients only, significantly lower mean CBF was identified in GBM tumor regions during, compared with before, Bev tx (p=0.04), while there was a non-significant tendency for CBF to be lower in the contralateral MCA territory during the same period (p=0.23) (**Fig. 1**). Using a linear mixed model incorporating all patient data to achieve higher statistical power, the trend for lower CBF in the contralateral MCA territory further approached statistical significance (p=0.14) (**Fig. 2**), while the drop in average CBF was found to be significantly greater in GBM compared with contralateral MCA regions (p<0.05).

Conclusions: Serial pCASL measurements show that CBF within GBM decreases during Bev tx. Additionally, there is a non-significant trend for CBF measurements in the

contralateral MCA territory to decrease as well. A small sample size, prior and concurrent chemo- and radiotherapies, and non-Bev CBF modifiers (such as caffeine) may confound the results.

Clinical Relevance: Bev appears to preferentially and directly target the tumor vasculature thereby decreasing tumor perfusion, although some mild decrease in global CBF may also occur.

REFERENCES – [1] Qiu D, *et al*, JMRI 2012 Jul;36(1):110-9, [2] Pinheiro JC and Bates DM. Mixed-Effects Models in S and S-PLUS. New York, USA: Springer; 2000, [3] Davidson AC, Hinkley DV. Bootstrap methods and their application. Cambridge, UK: Cambridge University Press; 1997.

ACKNOWLEDGEMENTS – NIH (5R01EB002711, 5R01EB008706, 5R01EB006526, 5R21EB006860, 5R01NS047607, 2P41RR009784), Lucas Foundation, Oak Foundation.

# Patients (# Scans)	Side	Mean ± SD		Δ†	%Δ†	p
		Before Bev	During Bev			
18 (53)*	GBM	70.4 ± 34.1	42.7 ± 24.7	-21.4	-32%	0.01
	Contra MCA	41.2 ± 8.7	35.3 ± 7.6	-3.8	-10%	0.14

Fig. 2 – Mean CBF of GBM and contra(lateral) MCA. *Included scans before or during bevacizumab therapy only. †Model-based change and % change in average CBF.