

Supertoroidal Analysis of Diffusion Tensor MRI of Patients with First-Episode Psychosis

Fabricio R S Pereira¹, Marcus V Zanetti¹, Maurício H Serpa¹, Tiffany Moukbel Chaim¹, Geraldo Busatto¹, Choukri Mekkaoui², and Marcel Parolin Jackowski³
¹School of Medicine, University of São Paulo, São Paulo, São Paulo, Brazil, ²Harvard Medical School, Boston, Massachusetts, United States, ³Computer Science, University of São Paulo, São Paulo, São Paulo, Brazil

Target Audience: Scientists and clinicians interested in the white matter changes involved in psychosis disorders described by Diffusion Tensor MRI.

Purpose: Diffusion Tensor MRI (DTI) provides the fractional anisotropy (FA) and mean diffusivity (MD) indices to characterize the axonal integrity and structure of the white matter (WM) fibers. Although abnormal levels of FA and MD have been associated with neuropsychiatric conditions¹, these indices showed to be insufficient to link brain abnormalities to their corresponding clinical symptoms. The supertoroid-based representation of the diffusion tensor yields two surrogate indices of diffusivity and degree of anisotropy, the toroidal volume (TV) and toroidal curvature (TC), respectively. They were successful to detect subtle differences in the cardiac myofiber architecture². Hence, here we assess how the toroidal indices perform in treatment-naïve patients with first-episode psychosis (FEP) versus healthy controls, and compare with findings using the traditional indices MD and FA.

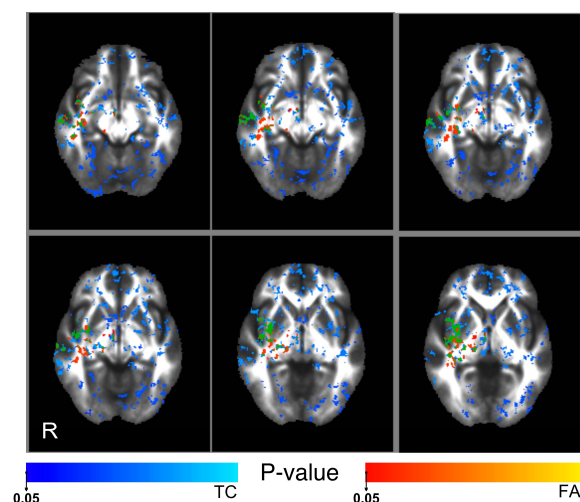


Fig. 1. FA (red) and TC (blue) map comparisons between control subjects (CG) and patients with first-episode psychosis (PG). R indicates right hemisphere. Minimum cluster size of 500 contiguous voxels for CG > PG of p-value < 0.05 corrected for multiple comparisons. Green clusters depict the overlapped areas between FA and TC maps for significant (p < 0.05) voxels.

superior longitudinal fasciculus and right corticospinal tract (Fig.2-red). TV showed changes in brain areas similar to those seen with MD when p < 0.1 (Fig.2-blue). TC was higher in CG than PG for right inferior fronto-occipital fasciculus, left superior longitudinal fasciculus, left uncinate fasciculus, right anterior thalamic radiation and right superior longitudinal fasciculus (Fig.1-blue). Intergroup TC comparisons showed more brain regions than FA and 46.64% of significant FA map was also part of the TC map. The overlap between MD and TV maps represents about 10% of MD map and 5.9% of TV map (Fig.2-Green).

Discussion: Although TV showed lower significant patterns of diffusivity when contrasted with MD, the overlap between both maps indicates that similar brain regions are involved. While TC and FA showed similar results, TC showed more circumscribed findings. This may be attributed to specificities of psychosis disorders but it may also be related to regional variability.

Conclusion: The supertoroidal representation provides a complementary approach to evaluate subtle microstructural brain abnormalities in psychosis disorders.

References: 1. M. E. Thomason, P. M. Thompson, *Annu Rev Clin Psychol* 7, 63; 2011. 2. C. Mekkaoui et al., *ISMRM*, 2011.

Material and Methods: DTI of 22 control (CG) subjects (8 female, mean age 26.64±6.89 years old) and 31 treatment-naïve FEP patients (PG) (11 female, mean age 27.41±7.26 years old) were acquired on a 1.5T Magnetom-Expre Siemens scanner using cardiac gating and parallel imaging. One diffusion-free image (b=0s/mm²) and diffusion-weighted images in 64 non-collinear directions (b=1000s/mm²) were acquired with parameters: TR/TE=8000/110ms, NEX=2, FOV=240mm, matrix=120x120 pixels, resolution=2.0x2.0x2.7mm, and a total of 50 slices. All participants provided written consent after being fully informed about the study. FA and MD maps were estimated with FSL toolbox (<http://fsl.fmrib.ox.ac.uk/fsl>). TV and TC were implemented into the AFNI software (<http://afni.nimh.nih.gov/afni/>). Randomized analysis was carried out using 500 permutations. p-value was corrected for multiple comparisons by applying the Threshold-Free Cluster Enhancement (TFCE). Significant results were considered when p < 0.05.

Results: CG subjects did not yield significant differences compared to PG in gender (chi=0.40; p=0.53) nor age (t-score=0.98; p=0.71). However, FA was higher in CG than PG for the right inferior fronto-occipital fasciculus, right inferior longitudinal fasciculus, right anterior thalamic radiation and callosal

body (Fig.1-red). MD was higher in PG than CG at left inferior fronto-occipital fasciculus; left anterior thalamic radiation; left

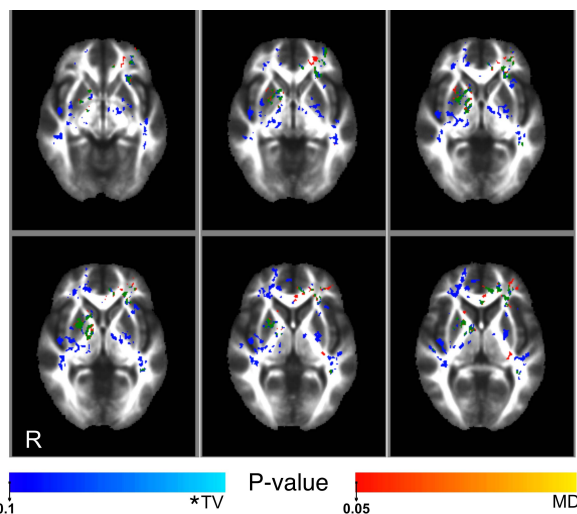


Fig. 2. MD (red) and TV (blue) map comparisons between CG and PG with Psychosis disorders. R indicates right hemisphere and "*" denotes p-values < 0.1. Green clusters depict the overlapped areas between MD and TV maps.