

Language Lateralization and Corpus Callosum Fractional Anisotropy in Patients with Brain Tumor: Combined Functional MRI with Diffusion Tensor Imaging

Kyung K Peck¹, Gabriella Tantillo², John Jyo², Rob Young², Nicole Brennan², Joanne Chou³, and Andrei Holodny²

¹Medical Physics and Radiology, Memorial Sloan-Kettering Cancer Center, New York, New York, United States, ²Radiology, Memorial Sloan-Kettering Cancer Center, New York, New York, United States, ³Statistics, Memorial Sloan-Kettering Cancer Center, New York, New York, United States

Purpose

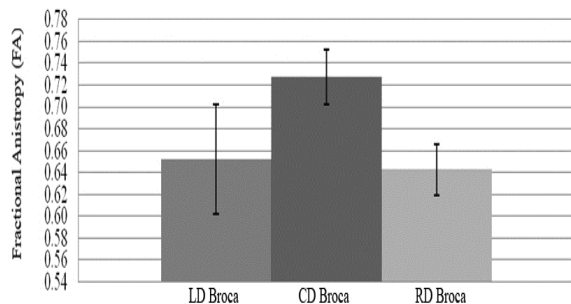
There have been conflicting studies looking at the morphology of the corpus callosum (CC) and lateralization of brain function in healthy subjects. Functional MRI (fMRI) and diffusion tensor imaging (DTI) have been used to investigate the relationship between fractional anisotropy (FA) in the corpus callosum (CC) and cortical language laterality (LI) measured in healthy controls (1,2,3). In this study, we sought to assess how brain pathology might impact the relationship between the CC microstructure and the degree of language lateralization by examining patients with brain tumors in the left hemisphere. We therefore combined data for the FA values in the anterior and posterior part of the CC in patients with left dominant (LD), right dominant (RD), or co-dominant (CD) language lateralization for patients with brain tumors in the left hemisphere.

Methods

20 right-handed patients with left hemispheric brain tumor were studied. fMRI and DTI studies were performed on a 3T GE scanner using echo planner imaging (EPI). Functional images were acquired with TR/TE=4000/40 ms; 128×128 matrix; 4.5 mm thickness. DTI was acquired using a single shot spin echo EPI sequence (25 directions, TR/TE=11000/64 ms, 128×128 matrix; 3 mm thickness, 1000 s/mm² b value). Image analysis was performed with AFNI software. The fMRI data were aligned using a 3D rigid-body registration and spatially smoothed with 4mm FWHM Gaussian filter. Functional activity from language tasks (phonemic fluency and verb generation) was generated using a cross-correlation analysis. Regions of interest (ROI's) were drawn for Broca's and Wernicke's area using anatomical landmarks and the number of activated voxels was counted for the ROIs. The lateralization index (LI) was calculated using the formula $LI = (L-R)/(L+R)$, and subjects were classified as right-dominant (RD), codominant (CD), or left-dominant (LD). For DTI analysis, ROI's of the anterior, posterior, and body of the corpus callosum using color fractional anisotropy (FA) maps were drawn. The FA values in the ROIs were calculated for each voxel and then averaged per region of the CC.

Results

For Broca's area, 8 patients were left-dominant for language tasks (average LI = 0.60), 8 patients were codominant (average LI = 0.05) and 4 patients were right dominant (average LI = -0.54). For Wernicke's area, there were 5 left-dominant patients (average LI = 0.46), 8 codominant patients (average LI = -0.02) and 7 right-dominant patients (average LI = -0.56). Figure shows a bar graph of average FA values of anterior portion of the CC for LD, CD and RD Broca's area activity. The Anterior CC FA was significantly higher for CD patients compared to LD and RD patients in Broca's area. Error bars represent the standard error. For the Anterior CC, mean FA values were 0.65, 0.74, and 0.64 for LD, CD, and RD groups respectively. On average, the CD group had higher median FA values than both the LD and RD groups. There was a borderline association between median FA and dominance group (p=0.09). Pair-wise



comparison showed no difference in FA value between LD and CD groups (p=0.145), and between LD and RD groups (p=0.67). However, there appeared to be a difference between RD versus CD group (p=0.07). For the posterior portion of the CC region, there was no statistically significant difference between any of the three groups (LD, CD and RD) on a Kruskal-Wallis test (p =.90) or with pair wise comparison between the LD and CD groups and the LD and RD groups.

Discussion and Conclusion

We found that as a group, patients who were left-dominant or right dominant for language in Broca's area had lower FA values in the anterior CC than those who were codominant for language. In contrast, there was no relationship between language dominance and posterior CC FA values for Wernicke's area. When patients were further sorted into lateralized vs codominant groups, codominant patients also had higher FA values in the anterior CC than patients who displayed strong lateralization in either the left or right hemisphere. The greater FA values in codominant patients may reflect a more directional microstructure for the corpus callosum in this region, suggesting a greater need for interhemispheric transfer of information. The presence of a brain tumor that encroaches upon functional cortical areas may trigger cortical reorganization as the brain adapts to tumor infiltration. This plasticity may be reflected in codominance as homologous language areas in the contralateral hemisphere may be recruited to assist in functional language tasks.

References

1 Josse G et al., Journal of Neuroscience, 2008;28(52):14132-14139, 2. Putnam MC et al., Journal of Neuroscience 2008;28(11):2912-2918, 3. Westerhausen et al., Brain Language, 2006;97(1):89-90.