

Multimodality Imaging Assessments of Response to Metformin Therapy for Breast Cancer in Nude Mice

yi mao¹, rui xia¹, lei wang¹, yuqing wang¹, and fabao gao¹

¹Department of Radiology, West China Hospital, Sichuan University, chengdu, sichuan, China

Purpose: Metformin: A Therapeutic Opportunity in Breast Cancer? Metformin in Cancer Therapy: A New Perspective for an Old Antidiabetic Drug? But there is few creditable studies have assessed the in vivo effects of metformin in cancer. We assessed the usefulness of diffusion-weighted imaging (DWI) and bioluminescence imaging (BLI) in evaluating tumor response to metformin.

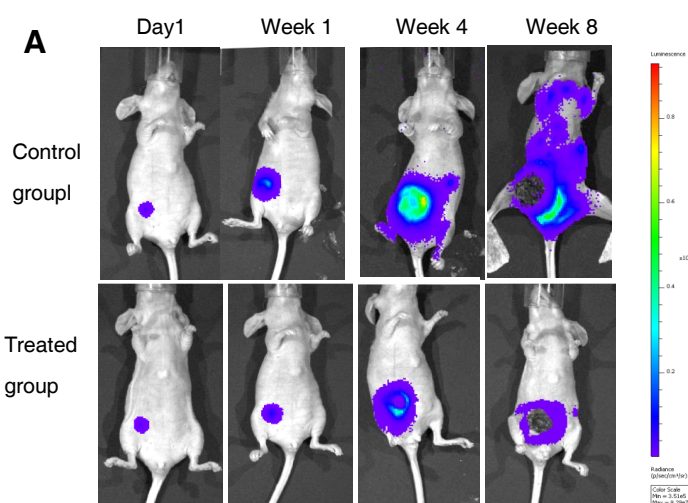
Materials and Methods: A luciferase-engineered human breast cancer cell line MDA-MB-231 was inoculated into the mammary fat pad of nude mice. Twelve female nude mice bearing tumors were divided into two groups. The mice in the treatment group were administered metformin (2 mg/mL in drinking water on each day) after tumor inoculation, and the mice in the control group were offered drinking water without any drug added. We performed 7T magnetic resonance imaging and optical imaging every week, which included T1- and T2-weighted imaging, DWI, and BLI. After imaging, the tumors were collected and subjected to histological analysis.

Results: Compared to the control group, the treatment group showed an obvious decrease in the mean bioluminescence (photons/s) of the tumors and fewer metastases. DWI showed that the apparent diffusion coefficient (ADC) value of the treated tumors increased gradually and was considerably higher than that of the control tumors, and there was a statistically significant difference between the control and treatment groups. Histological examination confirmed the metastasis.

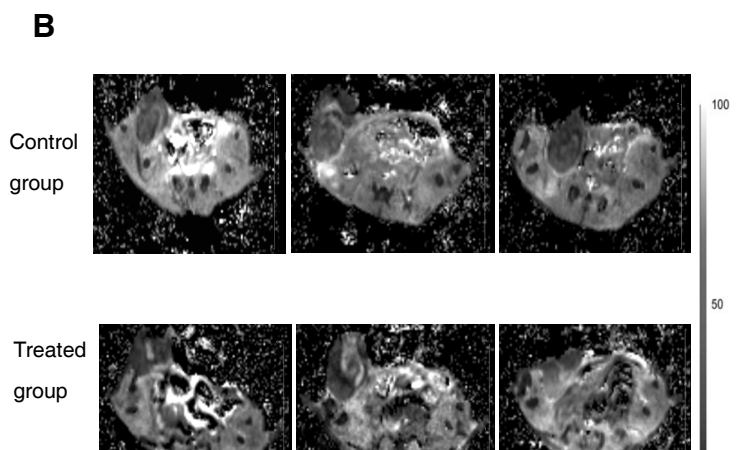
Conclusion: The growth and metastasis of MDA-MB-231 breast cancer may be inhibited by metformin. DWI and BLI have great potential in the evaluation of the early response to metformin treatment. BLI has a high degree of sensitivity, is able to detect micrometastases, can be used for tumor metastasis assessment in vivo.

References :

1. Liu B, Fan Z, Edgerton SM, Deng XS, Alimova IN, Lind SE, et al. Metformin induces unique biological and molecular responses in triple negative breast cancer cells. *Cell Cycle* 2009;8:2031–2040
2. Padhani AR, Liu G, Koh DM, Chenevert TL, Thoeny HC, Takahara T, et al. Diffusion-weighted magnetic resonance imaging as a cancer biomarker: consensus and recommendations. *Neoplasia* 2009;11:102-125
3. Patterson DM, Padhani AR, Collins DJ. Technology insight: water diffusion MRI--a potential new biomarker of response to cancer therapy. *Nat Clin Pract Oncol* 2008;5:220-233



(A) Images of representative mice from the control and treatment groups are shown from day 0 to 8 weeks after cell implantation. Tumor growth was monitored and quantified weekly by bioluminescent imaging (BLI).



(B) Representative apparent diffusion coefficient (ADC) maps. Images were obtained from 3-week-old tumors. The scale (from 0 to 100) indicates signal intensity when the maximum value was normalized to 100. Compared with the controls, the treated tumors exhibited a significant increase in ADC values.