

A METHOD FOR IDENTIFYING TUMOR SUB-REGIONS WITH SIMILAR ENHANCEMENT CHARACTERISTICS BASED ON VOLUMETRIC HIGH RESOLUTION DCE-MRI

Ergys Subashi^{1,2}, Everett J Moding³, James R MacFall^{4,5}, David G Kirsch³, Yi Qi^{2,5}, and G. Allan Johnson^{2,5}

¹Medical Physics Graduate Program, Duke University Medical Center, Durham, NC, United States, ²Center for In-Vivo Microscopy, Duke University Medical Center, Durham, NC, United States, ³Department of Pharmacology and Cancer Biology, Duke University Medical Center, Durham, NC, United States, ⁴Department of Biomedical Engineering, Duke University Medical Center, Durham, NC, United States, ⁵Department of Radiology, Duke University Medical Center, Durham, NC, United States

Introduction: Tumor neovasculature, often identified by leakiness, heterogeneous blood flow, and abnormal vessel diameter, is structurally and functionally different from healthy vessels. Dynamic contrast-enhanced (DCE) MRI has been widely used to study transfer kinetics between the intra- and the extra-vascular space, providing a set of *in-vivo* biomarkers useful in diagnosis and assessment of response to therapy [1]. The majority of studies measuring the effect of an anti-angiogenic agent have compared the mean value of these biomarkers on manually selected ROIs or over the entire tumor volume. These measurements include regions in the tumor where interpretation of the kinetic parameters is unclear (such as in necrotic areas) [2], or where the magnitude of response to therapy may be heterogeneous. We believe that incorporating semi-quantitative kinetic parameters to analyze DCE-MRI data, combined with a volumetric high spatial and temporal resolution acquisition, provides a technique for identifying tumor subpopulations that will potentially lead to an increase in sensitivity and specificity. In this work, we present findings from a cohort of five different tumors in which the histogram of the time-to-peak (TTP) parameter was used to automatically segment a tumor volume in regions of distinct enhancement patterns.

Methods: Experiments were performed in a 7-T, small animal, MRI scanner (Bruker BioSpin). An actively detuned volume excite RF-coil was used in conjunction with a 4-element array coil for surface receive. The DCE-MRI protocol was implemented using a 3D, interleaved, projection acquisition sequence with FOV=20x20x20 mm³, matrix=128x128x128, TR/TE=5/0.02 ms, NEX=1, FA=10°, BW=100 kHz, 1980 k-space views/interleave, and 13 interleaves. The k-space data were reconstructed using a keyhole, sliding-window, reconstruction algorithm allowing for a temporal resolution of 9.9 seconds/volume. The injection protocol was adapted from Loveless et al. [3]. Four tumor cell lines and a primary sarcoma model were studied: HT-29 (n=3), LoVo (n=3), MX-1 (n=3), and MDA-MB-232 (n=2) implanted in the mammary fat pad and a sarcoma (n=3) induced in the right hind leg. Tumors ranged in volume from 118 mm³–533 mm³. Time-intensity curves (TICs) were fit with a 4th-degree, 5-nodal spline curve, and the TTP was calculated on a pixel-by-pixel basis as the time in seconds it takes the signal to reach the maximum value. Maps of the area under the curve (AUC), and peak enhancement were also generated on a pixel-by-pixel basis. The extended Tofts model was used to calculate the rate of transport (K^{trans}) across the endothelium barrier.

Results: In all tumors studied, the TTP histogram could be used to clearly identify and segment at least three and up to five sub-populations of pixels with distinct distributions (Fig. 1a) as listed in Table 1. Representative TICs from a single pixel inside each of these sub-volumes are shown in Figure 1 (b-f). Regions 1, 2, and 5 were present in all cell lines studied. The presence or absence of regions 3 or 4 was not tumor-specific. The relative size of the peaks in the TTP histogram was also not tumor-dependent. The overlay of the segmented regions on the grayscale image (Fig. 2) reveals that these TTP sub-volumes are discrete with the fast-enhancing regions (low TTP) being located in the periphery and the slow-enhancing (high TTP) ones in the core of the tumor. The histograms of the area under the curve, peak enhancement, and K^{trans} did not have distinct peaks.

Conclusion: We have found that the histogram of TTP from a DCE-MRI study at a microscopic resolution (160- μ m isotropic voxels) can identify distinct regions in the tumor with similar enhancement kinetics. Three of these sub-populations (regions 1, 2, and 5) are present in all tumors studied. However, the TTP spectrum was not found to be tumor-specific. The segmented sub-volumes are located in predictable patterns, with the fast-enhancing regions in the periphery and slow-enhancing in the center of the tumor. Several groups have attempted to use the time-to-peak parameter as a semi-quantitative diagnostic biomarker in discriminating between benign/malignant lesions [4], or as a predictor for response to therapy [5]. It has been shown that there is a significant negative correlation between TTP and microvascular density suggesting an underlying physiologic mechanism as an explanation for diagnostic accuracy [6]. Preliminary results in our laboratory further suggest that the tumor sub-volumes identified by the TTP histogram may respond differently to therapy.

References: [1] O'Connor JPB, et al., *Nat Rev Clin Oncol* **9**: 167-177, 2012, [2] Sourbron SP, et al., *MRM* **66**: 735-745, 2011, [3] Loveless ME, et al., *MRM* **67**: 226-236, 2012, [4] Jansen SA, et al., *Radiology* **245**: 684-691, 2007, [5] Zahra MA, et al., *IJROBP* **74**: 766-773, 2009, [6] Yabuuchi H, et al., *Radiology* **226**: 345-354, 2003.

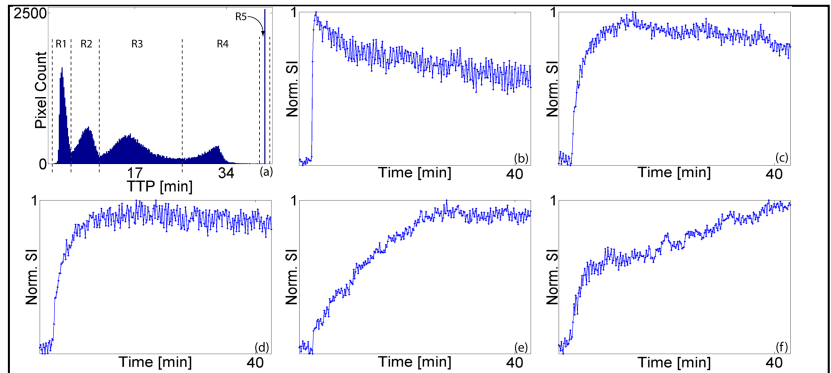


Figure 1. (a) Representative TTP histogram demonstrating the presence of 5 different regions (R1-R5). Normalized TIC from a single pixel in (b) region 1, (c) region 2, (d) region 3, (e) region 4, (f) region 5.

Table 1. Regions 1, 2, and 5 were clearly separated in all tumors studied (n=14). In six tumors, regions 3 and 4 were indistinguishable from adjacent regions.

TTP	0-300 sec (Region 1)	300-600 sec (Region 2)	600-1500 sec (Region 3)	1500-2400 sec (Region 4)	2400-2500 sec (Region 5)
n	14	14	8	3	14

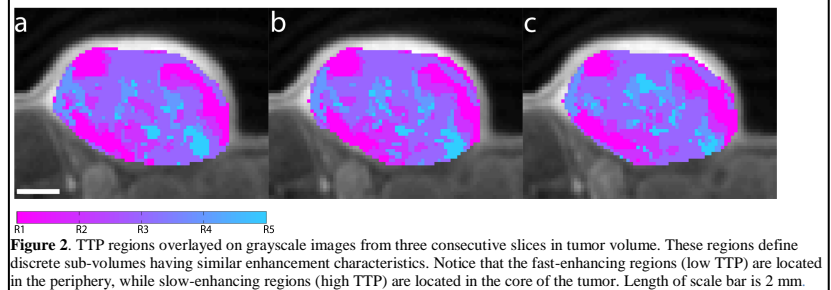


Figure 2. TTP regions overlaid on grayscale images from three consecutive slices in tumor volume. These regions define discrete sub-volumes having similar enhancement characteristics. Notice that the fast-enhancing regions (low TTP) are located in the periphery, while slow-enhancing regions (high TTP) are located in the core of the tumor. Length of scale bar is 2 mm.