

Discrimination of Prostate Cancer from Chronic Prostatitis: Comparison between Biexponential and Monoexponential Models

Wenchao Cai¹, Feiyu Li¹, Jintang Ye¹, Queenie Chan², Xiaoying Wang¹, and Xuexiang Jiang¹

¹Department of Radiology, Peking University First Hospital, Beijing, Beijing, China, ²Philips Healthcare, Hong Kong, China

Target Audience Radiologists, MR technologists and clinicians

Purpose Intravoxel incoherent motion (IVIM) MR imaging is a non-invasive method with the ability of separation of “pure” molecular diffusion and perfusion effects.¹ Some previous researches^{2,3} have compared the healthy and cancerous tissue using IVIM method. However, chronic prostatitis mainly contributes low diagnostic specificity of prostate cancer detection in the peripheral zone(PZ), which showed similar MR appearances with prostate cancer.⁴ Therefore the purpose of this study were to assess diffusion/perfusion IVIM features in histologically confirmed chronic prostatitis, prostate cancer and normal prostate PZ and compare with conventional DWI.

Methods The local ethics committee approved the study and 19 patients (mean 72±2years; range 57-84 years) with TRUS biopsy after MR examination were recruited into the study. The study was performed on a 3.0-T MRI scanner (Achieva 3.0T TX, Philips Healthcare, Best, The Netherlands) with 32-channel SENSE cardiac coil. The IVIM protocol was performed with a single-shot SE EPI sequence (five b-values 0, 188, 375, 563, 750 s/mm²; TR/TE 4114/75ms; FOV AP/RL/FH 160/180/66 mm; slices 22). Data were fitted with IVIM biexponential model using in-house software developed using IDL (Research Systems, Inc., USA) to obtain the diffusion coefficients (D) and perfusion fractions (f). The conventional DWI protocol included two DWI series: 0/800 and 0/1200 s/mm² were also performed to obtain the apparent diffusion coefficient (ADC₈₀₀, ADC₁₂₀₀) with monoexponential model using Diffusion software package in workstation (Philips Healthcare). The regions of interest (ROIs) were placed in the 114 sextant regions based on the sextant analysis, including pathologically confirmed prostate cancer (n=37), chronic prostatitis (n=36) and normal prostate PZ (n=41). The average D, f and ADC (ADC₈₀₀, ADC₁₂₀₀) for each region were computed respectively.

Results The mean D, ADC₈₀₀ and ADC₁₂₀₀ in the prostate cancer were significantly higher than those in chronic prostatitis and normal PZ (P<0.05, AVONA analysis) (Table 1, Figure 1). The mean f in the prostate cancer and chronic prostatitis were significantly higher than normal PZ (P<0.05). However, no significant difference of f was found between prostate cancer and chronic prostatitis (Table 1, Figure 1).

Discussion Chronic prostatitis demonstrated significantly higher diffusion characteristics than prostate cancer, while obviously higher perfusion and lower diffusion property than normal PZ detecting via IVIM analysis. The results of biexponential diffusion coefficient were not only comparable with that from monoexponential model and accordance with pathology results, but also showed the separation between prostate cancer and chronic prostatitis was greater for the biexponential diffusion coefficient than for the monoexponential model.

Conclusion IVIM allows for non-invasive characterization of biological changes (both perfusion fraction and diffusion) in prostate gland with chronic inflammation or prostate cancer, which may be of great potential in the better detection of prostate cancer.

References

- [1] Dixon W T. Radiology. 1988; 168(2):566-567.
- [2] Pang Y, Turkbey B, Bernardo M, et al. MagnReson Med. 2012.
- [3] Dopfert J, Lemke A, Weidner A and Schad L R. Magn Reson Imaging. 2011; 29(8):1053-1058.
- [4] Franiel T, Ludemann L, Rudolph B, et al. Invest Radiol. 2008; 43(7):481-487.

Group	D (×10 ⁻³ mm ² /s)	f (%)	ADC ₈₀₀ (×10 ⁻³ mm ² /s)	ADC ₁₂₀₀ (×10 ⁻³ mm ² /s)
Prostate cancer	0.78±0.23	10.6±4.89	1.06±0.19	1.02±0.23
Chronic prostatitis	1.24±0.20	10.7±3.04	1.24±0.22	1.28±0.19
Normal PZ	1.91±0.19	6.42±3.29	1.98±0.25	1.86±0.22

Table 1. Results of D, f, ADC₈₀₀ and ADC₁₂₀₀ in prostate cancer, chronic prostatitis and normal PZ.

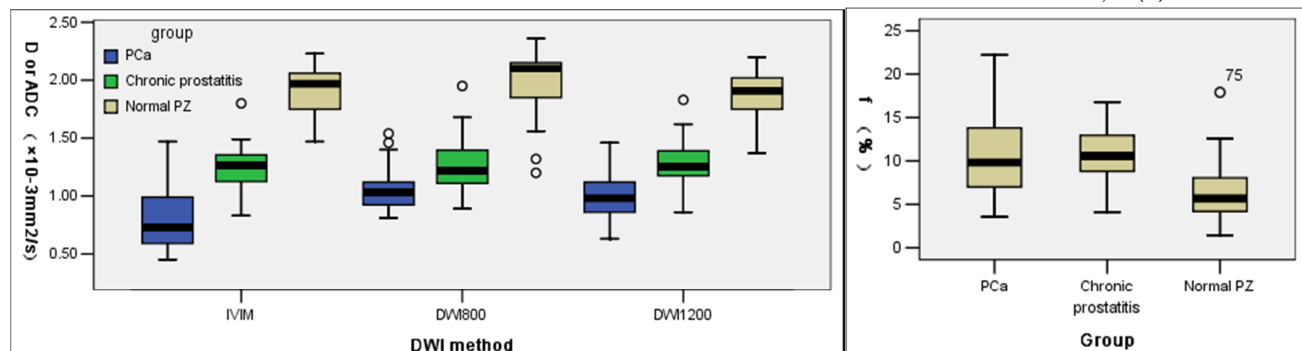


Figure 1. Boxplots of D, ADC₈₀₀, ADC₁₂₀₀ (Left) and f values (Right) show that the diffusion/perfusion changes in prostate cancer, chronic prostatitis and normal PZ.