

Predicting Malignancy in High-Risk Breast Cancer Patients: Evaluating Diagnostic Accuracy of Pre-Treatment Contrast-Enhanced MRI

Yousef Mazaheri¹, Charles W. Fry², Sandra B. Brennan², and Elizabeth A. Morris²

¹Medical Physics, Memorial Sloan-Kettering Cancer Center, New York, NY, United States, ²Radiology, Memorial Sloan-Kettering Cancer Center, New York, NY, United States

Introduction: High-risk breast cancer lesions include atypical ductal hyperplasia (ADH), lobular carcinoma in situ (LCIS), atypical lobular hyperplasia (ALH), papilloma, and radial scar. A major concern is that many women with high-risk lesions undergo unnecessary surgery and radiation treatment. However, if these lesions were properly identified, alternative clinical strategies (including no treatment) would be considered. The purpose of this study is to investigate predictive kinetic MRI characteristics for high-risk lesions to better stratify risk in high-risk breast cancer patients.

In the diagnosis of breast cancer, contrast-enhanced magnetic resonance imaging (CE-MRI) has shown to have very high sensitivity but moderate specificity. Several investigators have used dynamic contrast-enhanced (DCE-)MRI methods to improve the specificity of MRI in characterizing breast lesions. In DCE-MRI analysis, which typically uses the kinetic (time–signal intensity) curve, the washout pattern of the contrast agent is categorized qualitatively as 3 types: persistently enhancing (probably benign, Type I), plateau (intermediate probability for malignancy, Type II), and washout (probably malignant, Type III). However, qualitative analysis is prone to a wide range of reported intra- and interobserver variability.

Recently, Pedeconi et al reported on the role of breast MRI for predicting malignancy of histologically borderline lesions diagnosed at core needle biopsy (1). In their study, CE-MRI data of 32 patients classified as “borderline” were compared with histologic findings. The purpose of this study was to evaluate three empirical parametric models of enhancement (2) fitted to normalized CE-MRI data to quantify change in enhancement as a means to better stratify risk in high-risk breast cancer patients.

Methods: The institutional review board issued a waiver of informed consent for this HIPAA-compliant study. Twenty-seven breast cancer patients who underwent MRI fulfilled all inclusion criteria, which were that results of pathologic analysis from MRI-guided core-needle breast biopsy were available and CE-MRI were performed. *Lesion characteristics* – 10/32 were ADH lesions, 7/32 were ALH lesions, 1/32 were radial scars, and 13/32 were LCIS lesions. Histologic findings of samples obtained from surgically excised lesions were considered the reference standard

MR Image Acquisition – MRI examinations were performed with a 1.5- or 3.0-T whole-body MRI unit (GE Medical Systems, Waukesha, WI) equipped with a dedicated surface breast coil. As per the standard clinical breast MRI examination at our institution, the images obtained included a localization sequence followed by a T2-weighted fat-suppressed sequence and a T1-weighted non-fat-suppressed sequence.

CE-MRI – A simultaneous bilateral T1-weighted sagittal fat-suppressed sequence (flip angle, 35°; bandwidth, 32 kHz; field of view, 18–22 cm; matrix, 192 × 256; slice thickness, 3 mm; gap, 0 mm) was acquired before and three times after intravenous administration of 0.1 mmol/L gadopentetate dimeglumine (Magnevist; Bayer Health Care Pharmaceuticals, Montville, NJ) per kilogram of body weight; a 20-mL saline flush followed.

Image Analysis - Breast MR images were evaluated by an experienced radiologist and a region-of-interest (ROI) was placed on enhancing regions. The ROI was dilated by a semi-automatic method based on the method proposed by Mussurakis et al. (3). Three different parametric models of enhancement were fitted to the normalized data. These models were the Liner-slope model, Ricker model, and Gamma-variate model, recently presented as empirical parametric models to quantify change in enhancement (2, 4). Table 1 summarizes parameters calculated from the kinetic curves.

Results: Typical appearance on contrast-enhanced T1w images, and enhancement plots fitted to the three models: Gamma-variate model, Ricker model, and linear-slope model (Fig.1). A Comparison of estimated parameters from one of the three models (Linear-slope model) is shown for LCIS, ADH, and ALH lesions (Fig. 2). The p-value of the Wilcoxon Rank Sum test for the wash-out slope suggested statistically significant difference ($P < 0.05$) between the three lesions.

Conclusion: Our preliminary results suggest that breast CE-MR imaging and modeling of signal enhancement could play a role in the evaluation of lesions high-risk lesions.

REFERENCES: [1] Pediconi F, et al. Radiology. 2010;257(3):653-61. [2] Gal Y, et al. Conf Proc IEEE Eng Med Biol Soc. 2007;2007:71-4. [3] Mussurakis S, et al. Journal of computer assisted tomography. 1997;21(3):431-8. Mehnert A, et al. Proc Intl Soc Mag Reson Med2011; p. 2627.

Model	Parameters
Liner-slope model	Time to peak (TTP), Wash-in slope (WIS), Wash-out slope (WOS)
Ricker model	Scaling factor (A), 2 nd model parameter (b)
Gamma-variate model	Scaling factor (A), 2 nd and 3 rd model parameter (α, b)

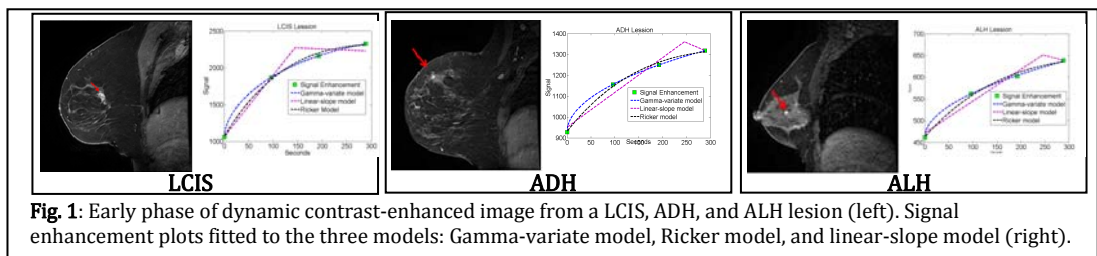


Fig. 1: Early phase of dynamic contrast-enhanced image from a LCIS, ADH, and ALH lesion (left). Signal enhancement plots fitted to the three models: Gamma-variate model, Ricker model, and linear-slope model (right).

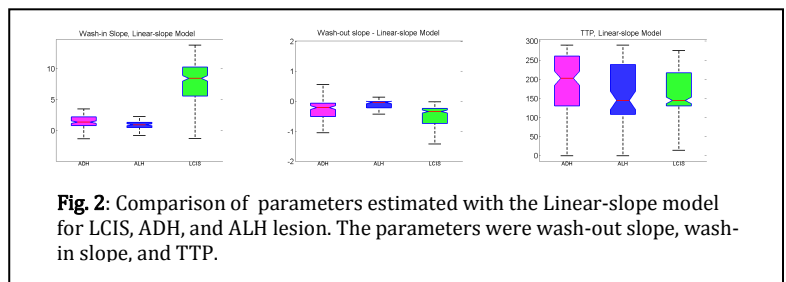


Fig. 2: Comparison of parameters estimated with the Linear-slope model for LCIS, ADH, and ALH lesion. The parameters were wash-out slope, wash-in slope, and TTP.