

Ferumoxytol Enhanced Resting State fMRI and relative cerebral blood volume, rCBV, mapping in Normal Human Brain

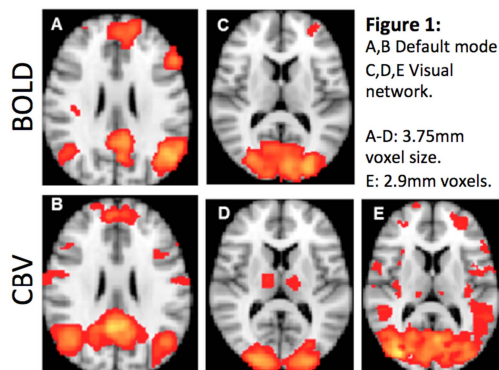
Helen Erica D'Arceuil¹, Alexandre Coimbra², Pamela Triano³, Margaret Dougherty³, Julie Mello³, Michael Moseley⁴, Gary Glover⁵, Maarten Lansberg⁶, and Francis Blankenberg⁷

¹Diagnostic Radiology, Stanford, Stanford, CA, United States, ²Genentech Inc, South San Francisco, CA, United States, ³Department of Rehabilitation Services, Stanford Hospital and Clinics, Stanford, CA, United States, ⁴Diagnostic Radiology, Stanford University, Stanford, CA, United States, ⁵Radiology, Stanford University, Stanford, CA, United States, ⁶Neurology and Neurological Sciences, Stanford Stroke Center, Stanford Hospital and Clinics, Stanford, CA, United States, ⁷Pediatric Radiology, Stanford Hospital and Clinics, Palo Alto, CA, United States

Introduction: The brain demonstrates spontaneous low-frequency (< 0.1 Hz) CBF fluctuations, measurable by resting-state functional MRI (RS-fMRI). Ultra small superparamagnetic iron oxide (USPIO) particles have been shown to enhance task-based fMRI signals (CBV-fMRI), compared to the BOLD effect, by a factor of ≈ 2.5 at 3T in primates (1) and humans (2). We evaluated the use of ferumoxytol for CBV-RS-fMRI and steady state relative CBV (rCBV) mapping in healthy volunteers with a view to employing this methodology for monitoring the brains of patients in stroke/cerebral trauma recovery and rehabilitation.

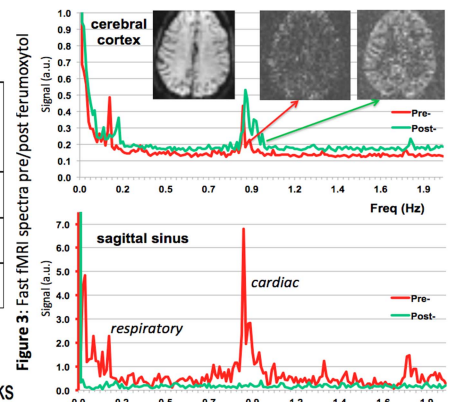
Methods: All procedures were approved by our local IRB board: 6 volunteers consented and enrolled in the study. A 3T GE Discovery MR 750HD scanner was used and the following sequences (before/after a bolus injection of 510mg ferumoxytol): 1) GRE-EPI 5min. resting state scans; TR 2400ms, TE 30 ms, 64², 2.9 mm slice pre-injection; TE 20 ms 64² & 96² post-ferumoxytol. 2) Dual-echo FSE TE 13/102ms, 3) GRE 8-echo TE 3.67 – 41ms, 4) Fast 4-slice GRE-EPI TR 250ms, TE 30 or 20ms. RS-fMRI data were processed using MELODIC (FSL, FMRIB, Oxford, UK) to generate Z score maps for independent components (IC). Pre/post R2, R2* and rCBV maps were calculated using MRVision (MRVision Co., Redwood City, CA). Parametric rCBV maps were calculated as follows: $[(R2^* \text{ post}-R2^* \text{ pre}) / \text{blood iron concentration}]$. Z score, rCBV maps were transformed to MNI152 space. rCBV values were averaged over the visual (Vis) and default mode (DMN) networks and mean rCBV, Z-statistics were compared between BOLD and CBV RS-fMRI ICs. Fast RS-FMRI data were Fourier transformed to evaluate the effect of ferumoxytol on cardiac and respiratory fluctuations in the brain BOLD/CBV signals.

Results: There were no adverse events following ferumoxytol infusion. All standard resting state networks (RSNs) were identified from BOLD and CBV ICs in all subjects at all resolutions. Figure 1 compares default mode and visual RSNs in one subject. On average the Z-scores and volumes of the Vis and DMN networks were comparable, however the absolute scale of signal fluctuations was greater with CBV contrast (median coefficient of variation increase 130%). There was a negative correlation between Z-scores in the DMN and rCBV for both BOLD and CBV contrast ($R^2=0.63, 0.76$) but not for the visual network. Overall there was relatively little variation in rCBV across subjects (coefficient of variation 15%). Intensity spectra from a fast acquisition are shown for the cortex and sagittal sinus, Fig.2. Cardiac (~ 1.0 Hz) and respiratory (~ 0.2 Hz) fluctuations generally decreased to baseline within large vessels post ferumoxytol. Changes in intensity of cortical cardiac and respiratory signals varied individually; increased (n=3) or decreased (n=1) post ferumoxytol. Fig 2. Shows an individual with increased cardiac fluctuations in the cortex after ferumoxytol injection.



Series	Visual Z score	Visual volume (mm ³)	DMN Z score	DMN volume (mm ³)
BOLD	4.54±0.73	195±55	4.38±0.25	197±28
CBV	4.71±1.07	143±49	4.22±0.21	233±50
CBV 96	4.05±0.72	178±76	4.39±0.67	181±38

Table 1: Group (mean ± SD) Z statistic and volume (threshold at Z=2) for the Visual and default mode networks



Discussion & Conclusions: Ferumoxytol enhanced CBV-RS-fMRI is robust and shows the expected major networks similar to the BOLD effect at 3T. Increased cardiac, respiratory signals post ferumoxytol in some individuals suggests that correcting for these effects will be more important with CBV-RF-fMRI. The robustness of the CBV contrast may be advantageous in studies of patients where head motion is more problematic and task-based paradigms are often challenging. In some individuals, additional areas of activation were observed within standard networks with CBV-RS-fMRI compared to BOLD. Further group analysis is underway.

References: (1) Mandeville et al, ISMRM, 2010: P1110. (2) Qui et al, Neuroimage; 2012:459.