

Reconstructing cerebellar-cortical connections with advanced diffusion tractography

Fulvia Palesi^{1,2}, Donald Tournier^{3,4}, Fernando Calamante^{3,4}, Niels Muhlert⁵, Gloria Castellazzi^{2,6}, Declan Chard⁵, Egidio Ugo D'Angelo^{2,7}, and Claudia Angela M Wheeler-Kingshott⁵

¹Department of Physics, University of Pavia, Pavia, Italy, ²Brain Connectivity Center, IRCCS C. Mondino, Pavia, Italy, ³Melbourne Brain Centre - Austin Campus, The Florey Institute of Neuroscience and Mental Health, Heidelberg, Victoria, Australia, ⁴Department of Medicine, Austin Health and Northern Health, University of Melbourne, Melbourne, Australia, ⁵NMR Research Unit, Queen Square MS Centre, Department of Neuroinflammation, UCL Institute of Neurology, London, United Kingdom, ⁶Department of Industrial and Information Engineering, University of Pavia, Pavia, Italy, ⁷Department of Public Health, Neuroscience, Experimental Medicine, University of Pavia, Pavia, Italy

Target Audience: Clinicians and physicists with an interest in brain structure and function.

Purpose: The cerebellum is a complex brain structure and *in vivo* study of its connectivity networks, especially with cerebral structures, is challenging. Most previous studies have assessed cerebellar connections using physiological and tract tracing approaches in animals but few have focused on MRI investigations in human brain [1]. None of these MRI studies have attempted high-resolution reconstruction of whole contralateral cerebellar-cortical tracts. This study assessed the feasibility of using advanced diffusion imaging methods to reconstruct these tracts *in vivo*. To achieve this, we combined two techniques: track reconstruction with a constrained spherical deconvolution (CSD) algorithm [2,3] and seed/target placement through the creation of super-resolution maps using track density imaging (TDI) [4].

Methods: MRI acquisition: We performed diffusion weighted imaging (DWI) scans on 15 healthy controls (HC) (mean age 36.1 yrs, 8 females and 7 males) using a Philips Achieva 3T MRI scanner (Philips Healthcare, Best, Netherlands) with a 32-channel head coil. All data were acquired using a cardiac-gated SE-EPI sequence. The imaging parameters were: TR = 24 s [depending on the cardiac rate], TE = 68 ms, SENSE factor = 3.1, 72 axial slices with no gap, acquisition matrix = 96×112, reconstruction matrix = 112×112, 2 mm isotropic voxel, 7 images with b = 0 and 61 optimised non-collinear diffusion weighted images with b = 1200 s/mm²[5]. Diffusion analysis: DWI data were analysed using FSL [6] and MRtrix [3] software packages. Eddy current correction and brain extraction were performed using FSL. DWI data were realigned along the superior/inferior (S/I) direction to the MNI-152 template, in order to overlap decussation from all subjects, by using a rigid body transformation (6-degrees of freedom, FLIRT, FSL) to avoid any shape deformations. Whole brain tractography was obtained with MRtrix by using an algorithm that combines the CSD technique with probabilistic streamlines tractography; the relevant parameters were: seed = whole brain, step-size = 0.1 mm, maximum harmonics order = 8, 2500000 tracks. From these tracks, a TDI map at 1 mm resolution was created as the total number of tracks passing within each element of the user-defined grid (1 mm in our case). Separately, on the b0 and TDI images, we placed spherical seed ROIs (radius = 2 mm) centred on the superior cerebellar peduncle (SCP) in each cerebellar hemisphere. In order to select contralateral fibre pathways, we also defined one target ROI per seed ROI (right/left), on the whole contralateral red nucleus. The output of the whole brain tractography was used to reconstruct cerebellar tracts from the SCP through the contralateral red nucleus and towards the cerebral cortex. Two different tracts for each superior cerebral peduncle were created: one using ROIs drawn on the b0 image and the other using ROIs drawn on the TDI map. Diffusion tensor components were also calculated using MRtrix and the FA map was created, in order to analyse the FA trend along the cerebellar tracts parcellated using MRtrix along the inferior/superior direction because this is often used in clinical studies to compare patients and healthy groups [7].

Results: The results shown in the Figures are from one randomly selected subject, but the findings were consistent among all cases. We found that the combined use of CSD and probabilistic tractography successfully reconstructed cerebellar tracts to the contralateral cortical region (see Fig 1 showing the cerebellar-prefrontal tract). We qualitatively compared tracts reconstructed using seed/target ROIs placed on b0 with those reconstructed using seed/target ROIs placed on TDI (Fig 2). In the latter case we were able to isolate and reconstruct only cerebellar tracts originating from the SCP, avoiding all other cerebellar tracts (such as those running through the inferior peduncle; Fig 3). A quantitative comparison of tracts' indices, aligned in the inferior/superior direction across subjects, was performed on the average FA along the S/I direction of the tracts in all subjects (see Fig 4). This shows that whilst the FA is remarkably similar after the decussation, it differs in the inferior slices, corresponding to cerebellar regions, with an increased inter-subject variability in the tracts generated using b0 ROIs.

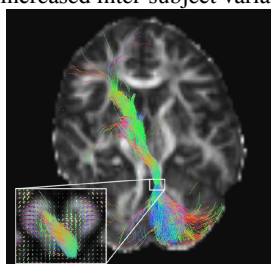


Figure 1: Cerebellar-cortical tract and decussation detail

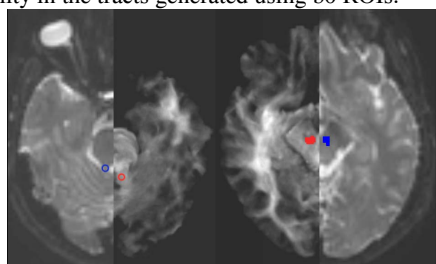


Figure 2: Example of seed (left) and target (right) ROIs drawn on b0 image (blue) and TDI map (red).

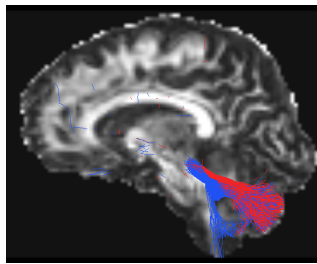


Figure 3: Example of tract on b0 image (blue) and on TDI image (red)

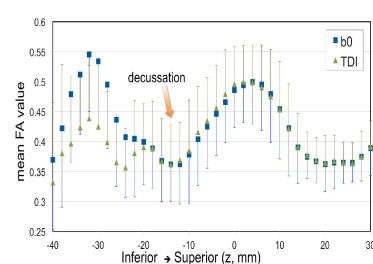


Figure 4: Trend of average FA value on all subjects.

Discussion and conclusions: In this work we addressed the issue of cerebello-cortical tracts reconstruction through decussating fibres. We chose a reconstruction method based on CSD rather than single tensor calculation, together with probabilistic tractography. By using this approach we could reconstruct the known contralateral cerebellar-cortical tracts originating from both left and right SCP, which are missed using standard tractography methods. Moreover we compared two different images for ROIs definition (i.e. b0 images and TDI maps). Tracts appeared more anatomically accurate when using TDI maps rather than b0 images (Fig 2). The inter-subject variability of cerebellar FA, often used to detect pathological changes in clinical studies, was found to be more reproducible when using ROIs placed on TDI. Future work will assess the effects of non-linear registration to a target space on the tracts and the application of this method to assess specific aspects of cerebellar connectivity in brains affected by disease.

Acknowledgments:

MS Society of Great Britain and Northern Ireland, International Spinal Research Trust, UCLH/UCL Comprehensive Biomedical Research Centre for funding

References: [1] Granziera C et al. *PLoS ONE* 2009; 4(4):e5101; [2] Tournier JD et al. *NeuroImage* 2007; 35:1459-1472; [3] Tournier JD et al. *International Journal of Imaging Systems and Technology* 2012; 22(1):53-66; [4] Calamante F et al. *NeuroImage* 2010; 53(4):1233-1243; [5] Cook PA et al. *J Magn Reson Imaging* 2007; 25(5):1051-8; [6] *FMRIB Software Library*, <http://www.fmrib.ox.ac.uk/fsl/>; [7] Lin F et al. *NeuroImage* 2006; 33:154-160.