

# Does the signal arising from a single fascicle significantly deviates from a monoexponential decay with a clinical scanner?

Benoit Scherrer<sup>1</sup>, Maxime Taquet<sup>1,2</sup>, Onur Afacan<sup>1</sup>, and Simon K. Warfield<sup>1</sup>

<sup>1</sup>Computational Radiology Laboratory, Boston Children's Hospital, Harvard Medical School, Boston, MA, United States, <sup>2</sup>ICTEAM Institute, Université catholique de Louvain, Louvain-la-Neuve, Belgium

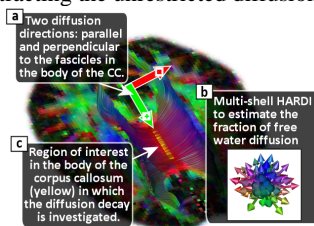
**Introduction.** Multiple works have shown that the diffusion attenuation *in a voxel* significantly deviates from a monoexponential decay, providing evidence that the Gaussian assumption underlying diffusion tensor imaging (DTI) is not appropriate to accurately represent the diffusion-weighted (DW) signal in the voxel. The biophysical mechanisms responsible for this non-monoexponential behavior are numerous and remain under investigation [Yablonskiy2003, Schwarcz2004, Assaf2005, Minati2007, Mulkern2009]. Particularly, it can arise from the presence of multiple fascicles with heterogeneous orientations in voxels (intra-voxel orientation heterogeneity, IVOH) [Minati2007]. Additionally, when using short diffusion pulse duration  $\delta$ , it may reflect the mixing of unrestricted (free) diffusion, hindered diffusion (arising from water molecules bouncing on the membranes of the cells in the extra-axonal space) and restricted diffusion (arising from the water molecules in the intra-axonal space) for each fascicle [Assaf2005]. However, when imaging with a clinical scanner *with long*  $\delta$ , long echo time (TE) and low signal-to-noise ratio, it is not clear that a non-monoexponential decay can be observed for *a single fascicle*. In this work we hypothesize that, with a clinical scanner, the observed signal arising from a single fascicle may be monoexponential and that the non-monoexponential behavior observed *in voxels* may reflect predominantly the IVOH and the presence of an additional compartment that is macroscopically isotropic at the measured diffusion scale. We focused on imaging a region containing a single fascicle orientation, the body of the corpus callosum (CC, Fig.1), to eliminate the effect of IVOH. We estimated the parameters of an unrestricted diffusion compartment and investigated the residual diffusion decay when subtracting the contribution of unrestricted diffusion.

**Method.** Diffusion-weighted magnetic resonance imaging was carried out on a healthy volunteer using a Siemens 3T Trio clinical scanner with a 32 channel head coil (FOV=220mm, matrix=128x128, in-plane resolution=1.7x1.7mm<sup>2</sup>, slice-thickness=2.0mm, TE=126ms, TR=3sec). We first performed an experiment to determine the optimal DWI protocol that ensures uniform SNR across increasing b-values. To this end, we acquired various b-value images between 500 and 5000 in which we measured the SNR. We performed a regression analysis to describe the SNR as a function of the b-value and determined the number of repetitions  $N_{\text{repetition}}(b)$  necessary to ensure uniform SNR across all b-values, given by:

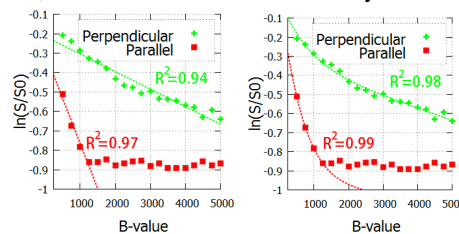
$$N_{\text{repetition}}(b) = \lceil 24 / (47.14 \exp(-0.0033b) + 32.36 * b^{-0.199}) \rceil^2 \quad (1)$$

We then focused on imaging the body of the corpus callosum (Fig.1). We measured the diffusion attenuation in both the parallel and perpendicular directions with respect to the fascicles (Fig.1a), with various b-values ranging from 500 to 5000 by increments of 250 with constant  $\delta$  and constant diffusion time separation  $\Delta$ , by modulation with various diffusion gradient norms. The number of repetition for each b-value was determined by using Eq.1, resulting in up to  $N_{\text{repetition}}(5000)=17$  repetitions for b=5000 and a total of 548 DW images. We acquired 15 slices with TR=3secs, long enough to avoid any T1-weighted signal. We also imaged a multi-shell HARDI (Fig.1b) composed of 5 b=0 images, 30 b=1000 images and 15 images at each of b=1500, b=2000, b=2500 and b=3000, leading to a total of 95 images. The gradient orientations were maximally separated across the shells using the electrostatic repulsion model between multiple subsets [Cook2007]. We investigated the diffusion decay in a ROI of the CC (Fig.1c) both in the parallel and perpendicular direction with respect to the fascicles (see Fig.2). The ROI was carefully selected to avoid any partial voluming with CSF. We considered a multi-compartment model with one fascicle represented by a full tensor and an unrestricted compartment modeled by an isotropic tensor. The parameters were estimated using the multi-shell HARDI (Fig.1b). We subtracted the estimated amount of unrestricted diffusion to the original DW signal and investigated the residual attenuation (Fig.3).

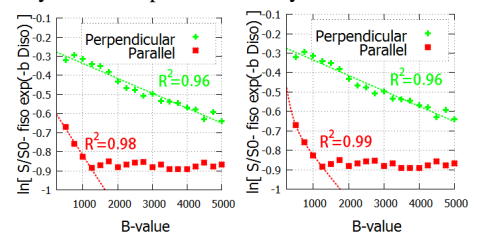
**Results.** Fig.2 shows that when ignoring the unrestricted diffusion, the signal arising from the densely aligned fascicles of the CC *significantly* deviates from a monoexponential in the perpendicular direction (radial diffusion), *even at moderate b-values*. In contrast, Fig.3 shows that when subtracting the unrestricted diffusion contribution, the residual radial diffusion decay is well described by a monoexponential decay.



**Fig.1. Experimental settings.** We performed one acquisition with only two direction and a lot of b-values to investigate the diffusion decay and one multishell HARDI acquisition to make possible the estimation of the isotropic diffusion compartment.



**Fig.2. Diffusion attenuation in the body of the corpus callosum : monoexponential (left) and biexponential (right) fit.** The non-linearity of  $\ln(S/S_0)$  shows that the decay is significantly non monoexponential in the perpendicular direction with respect to the fascicles, even at low b-values (S: DW signal; S0: non-DW signal).



**Fig.3. Remaining diffusion signal after subtraction of the contribution of the unrestricted diffusion : monoexponential (left) and biexponential (right) fit.** It shows that the remaining signal is well described by a monoexponential decay.

**Conclusion.** Our results indicate that with a clinical scanner with long  $\delta$ , when subtracting the contribution of unrestricted diffusion, the remaining radial signal arising *from a single fascicle* is well described by a monoexponential decay. When modeling the unrestricted diffusion with an isotropic tensor, each single fascicle may be well represented by a diffusion tensor. We speculate that, with long  $\delta$  as generally utilized to minimize TE and maximize the SNR [Yeh2010], each spin has sufficient time to bounce on the membranes of the cells (hindered diffusion) and to explore a large portion of the space. The spin position tagged by the first diffusion pulse is the mean of all positions over the explored space and that average position is very close to the one untaged by the second diffusion pulse. This may explain the little observable evidence of hindered diffusion at long  $\delta$ . A limitation of our experiment may be the long TE leading to a relatively low SNR. The parallel attenuation reaches the noise floor very rapidly and additional low b-value measurements may be required for its characterization.

**References.** [Assaf2005] Assaf Y, Basser PJ, Composite hindered and restricted model of diffusion (CHARMED) MR imaging of the human brain. Neuroimage, 2005, 27, 48-58. [Cook2007] Cook PA et al., Optimal acquisition orders of diffusion weighted MRI measurements, J Magn Reson Imaging, 2007, 25, 1051-1058 [Minati2007] Minati L, Wglarz WP, Physical foundations, models, and methods of diffusion magnetic resonance imaging of the brain: A review, Concepts Magn Reson, 2007, 30A, 278-307. [Mulkern2009] Mulkern R et al., On high b diffusion imaging in the Human brain: ruminations and experimental insights, Magn Reson Imaging, 2009, 27, 1151-1162. [Schwarcz2004] Schwarcz A et al., The existence of biexponential signal decay in magnetic resonance diffusion-weighted imaging appears to be independent of compartmentalization, Magn Reson Med, 2004, 51: 278-285 [Yablonskiy2003] Yablonskiy DA et al., Statistical model for diffusion attenuated MR signal, Magn Reson Med, 2003, 50, 664-669 [Yeh2010] Yeh, C.H et al., The effect of finite diffusion gradient pulse duration on fibre orientation estimation in diffusion MRI, NeuroImage, 2010, 51(2), 743-751