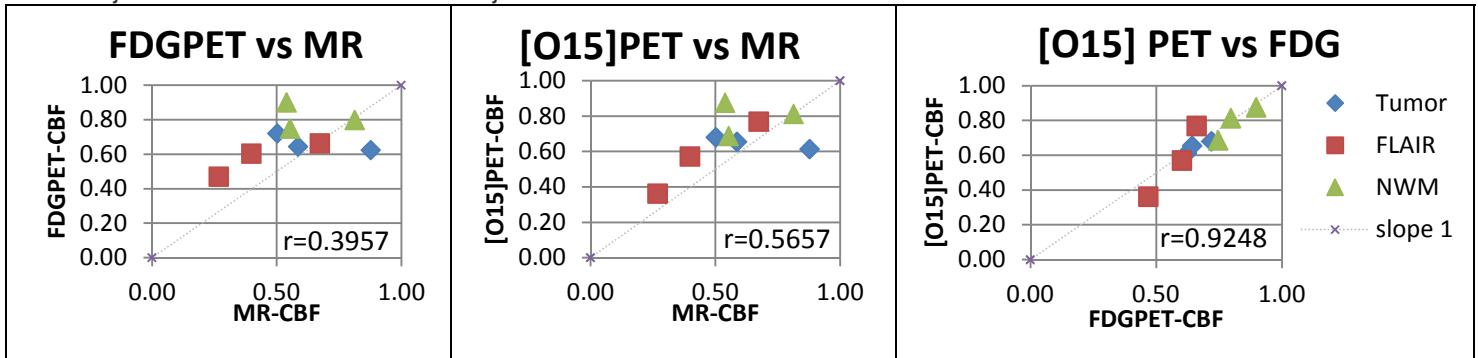


Objective: Cerebral blood flow (CBF) has been compared using PET and MR methods but not using a PET/MR dual-modality imaging system. In this study we compare CBF measurement obtained using three methods: dynamic susceptibility contrast (DSC) MR, Dynamic F18-FDG, and O-15 water PET scans for patients with brain tumors. We use a newly developed PET/MR scanner (Siemens Biograph mMR) which was approved for commercial use in 2011. This integrated system simultaneously acquires MR and PET images within a single examination with lower radiation dosage.

Methods: 2 patients (a 52 year old female and a 65 year old male) with non-small lung cancer metastatic brain tumors were examined in this study. Imaging acquisition: O-15 water PET scan was performed on an EXACT HR+ 962 scanner (Siemens) with injection of approximately 50 mCi of radioactive tracer. Dynamic F18-FDG scans was done on a PET/MR scanner (Siemens Biograph mMR) for 60 minutes simultaneously with MR scans including structural T1 weighted MPRAGE, dynamic susceptibility contrast (DSC) MR with a bolus contrast gadolinium injection. FLAIR and T1 post gadolinium contrast imaging was also performed to facilitate tumor region-of-interest (ROI) definition. Image analysis: Intra-subject cross-modality image registration, i.e. O15-PET to FDG-PET, etc. was performed using vector-gradient method implemented using in-house software [1]. Relative cerebral blood flow (CBF) was calculated based on the O15-water studies by identifying a 1-minute time window after arriving of the contrast bolus, with the summed image being a close representation of regional CBF [2]. It is also well known that cerebral glucose metabolic rate (CMRglu) is highly correlated with CBF, and the image intensities of late frames of a dynamic FDG-PET scan is proportional to regional CMRglu [3], therefore the 30-60 minutes of FDG-PET data was summed as an additional approximation of CBF. MR based CBF measurement was obtained using the FDA approved vendor provided software on the console. To facilitate comparison of images obtained at different spatial resolution, images from all modalities were preprocessed to achieve a common resolution of 8mm full-width-half-max (FWHM). Voxel-wise correlation between O15-water based CBF, FDG-PET, and MR based CBF was examined within a whole brain mask determined based on atlas registration of the anatomical MPRAGE to a brain atlas. In addition, CBF measurement for tumor, edema, contra-lateral normal white matter and thalamus were obtained using Analyze (Mayo Clinic).

Results: Whole brain voxel-wise (WBVW) correlation observed between MR-CBF and [O15]PET-CBF was 0.66 for the first subject and 0.54 for the second subject; WBVW correlation between FDGPET-CBF and [O15]PET-CBF was 0.85 for the first subject and 0.83 for the second subject. The correlation between MR-CBF and FDGPET-CBF was 0.62 for the first subject and 0.47 for the second subject.



Relative CBF's for selected ROI lesions compared to thalamus are shown above with the correlation values of: MR-CBF and FDGPET-CBF=0.3957; MR-CBF and [O15]PET-CBF = 0.5657; FDGPET-CBF and [O15]PET-CBF=0.9248.

Conclusion: The capability of simultaneous PET and MR acquisition on the Biograph mMR scanner allows us to directly compare MR and PET hemodynamic imaging techniques without the potential interference caused by spontaneous fluctuations of these physiological parameters. In this preliminary study, we performed simultaneous FDG PET and MR acquisition on the mMR scanner. MR based CBF were found to be correlated with PET CBF at both voxel and regional level, although the correlation was lower than the correlations between [O15]PET and FDG imaging. Further investigation is ongoing to investigate the difference between PET and MR based CBF measurements, and additional study participants are being enrolled.

References: [1] Rowland DJ et al., Registration of [18F]FDG microPET and small animal MRI., Nucl. Med. Biol 2005; 32: 567-572
 [2] Vaishnavi, S.N., et al., Regional aerobic glycolysis in the human brain. Proc Natl Acad Sci U S A, 2010.
 [3] Rostomian, A.H., et al., Early 11C-PIB frames and 18F-FDG PET measures are comparable: a study validated in a cohort of AD and FTLD patients. J Nucl Med, 2011. 52(2): p. 173-9.