

CEREBRAL PERFUSION LEVELS REFLECT WHITE MATTER INJURY IN PRETERM INFANTS

Ruth L O'Gorman¹, Hans Ulrich Bucher², Brigitte Koller², Hadwig Speckbacher¹, David C Alsop^{3,4}, Ajit Shankaranarayanan⁵, Jean-Claude Fauchere², and Cornelia Hagmann²

¹University Children's Hospital, Zurich, CH, Switzerland, ²University Hospital, Zurich, CH, Switzerland, ³Beth Israel Deaconess Medical Center, Boston, MA, United States, ⁴Harvard Medical School, Boston, MA, United States, ⁵Global Applied Science Laboratory, GE Healthcare, Menlo Park, CA, United States

Target audience: Researchers interested in perfusion imaging and neonatal MRI

Purpose: Diffuse white matter injury is the most prominent brain injury reported in preterm infants and is associated with significant neurodevelopmental impairment.¹ Since cerebral ischemia represents a major risk factor for white matter injury, perfusion abnormalities in preterm infants may reflect a selective vulnerability to brain injury. Perfusion may therefore provide an early biomarker for cerebral injury and neurodevelopmental outcome. The purpose of this study was to investigate the link between cerebral perfusion and white matter injury in preterm infants.

Methods: The patient group consisted of 17 preterm infants (10 male) born between 26 and 31 weeks gestation. MR imaging studies were performed at term-equivalent age (37-43 weeks) with a 3T GE HD.xt TwinSpeed MRI scanner (GE Healthcare, Milwaukee, WI, USA), using an 8-channel receive-only head coil. All infants were scanned during natural sleep. The structural MRI protocol included axial T2-weighted FSE (TE/TR = 102/5640, resolution 0.4x0.4x2.5 mm³), coronal PD/T2-weighted FSE (TE=26/128 ms, TR=6600 ms, resolution 0.7x0.7x1.5 mm³), and axial T1-weighted SPGR images (TE/TR= 2.6/5.7ms, TI=750 ms, flip angle = 12, resolution=0.8x0.8x1.4 mm³). Cerebral perfusion images were acquired using a background suppressed pulsed continuous arterial spin labeling (pCASL) sequence, and normalized to a group-specific neonatal perfusion template. White matter injury was assessed from the structural MR images using a standardized scoring system² consisting of a 3-point scale ranging from 1 (normal) to 3 (moderate-severe abnormality) applied to five areas of assessment, (nature and extent of white matter abnormality, periventricular white matter volume loss, cystic abnormalities, ventricular dilatation, and thinning of the corpus callosum). A total white matter injury score was calculated as the sum of the injury scores for each area of assessment, and the correlation between perfusion and white matter injury was assessed on a voxel-wise basis by permutation testing.

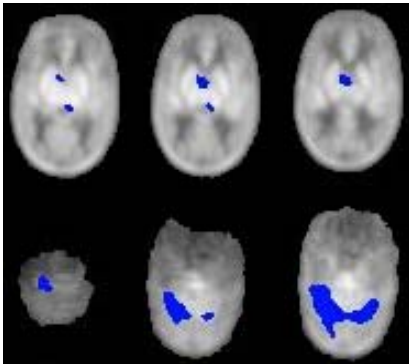


Figure 1. Clusters demonstrating a significant negative correlation between perfusion and white matter injury ($p < 0.05$, corrected).

evidence that these regions are functionally as well as structurally abnormal in preterms, and suggests that perfusion may reflect a selective vulnerability to lesions in these areas and in the cerebral white matter. The decreased perfusion in the cerebellum in infants with white matter injury may also underlie the smaller cerebellar volumes previously observed in preterms with supratentorial lesions⁵, associated with impaired outcome. Neurodevelopmental follow-up data should help to clarify the developmental significance of these findings, and offer insight into the potential utility of cerebral perfusion as a biomarker for neurological outcome in preterm infants.

Conclusion: White matter injury in preterms is associated with decreased perfusion in the cerebellum, thalamus, and basal ganglia, suggesting that perfusion may reflect a selective vulnerability to cerebral injury in high risk neonates

References

1. Volpe JJ. Lancet Neurol 2009; 8: 110-24
2. Woodward LJ, et al. N Engl J Med 2006;355:685-94.
3. Chugani HT, et al. Ann Neurol 1987; 22:487-497
4. Miranda MJ, et al. Pediatric Research 2006; 60:359-363
5. Srinivasan L, et al. AJNR March, 2006; 27: 573-579

Results: Perfusion was increased in the basal ganglia, brainstem, and sensorimotor areas relative to other cortical and subcortical regions, as described previously.^{3,4} White matter injury scores were negatively correlated with perfusion in the cerebellum, basal ganglia, and thalamus ($p < 0.05$, corrected; see figures 1 and 2).

Discussion: Structural brain abnormalities in preterm infants are typically manifested in a characteristic pattern of injury affecting the cerebral white matter, thalamus, cerebellum, basal ganglia, brainstem, and cerebral cortex.¹ The observed link between white matter injury and decreased perfusion in the cerebellum, basal ganglia, and thalamus provides evi-

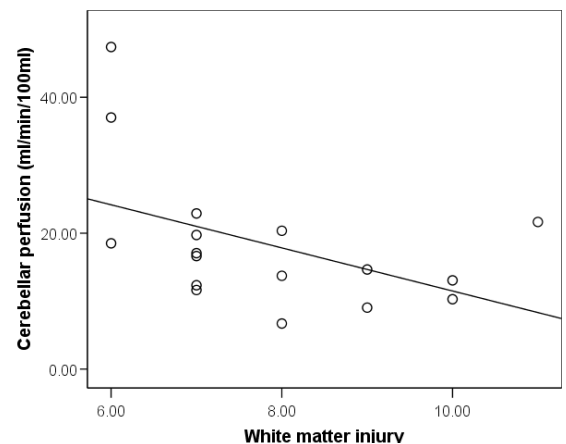


Figure 2. Scatterplot showing the extracted perfusion values from the significant cluster in the cerebellum, plotted against white matter injury scores.