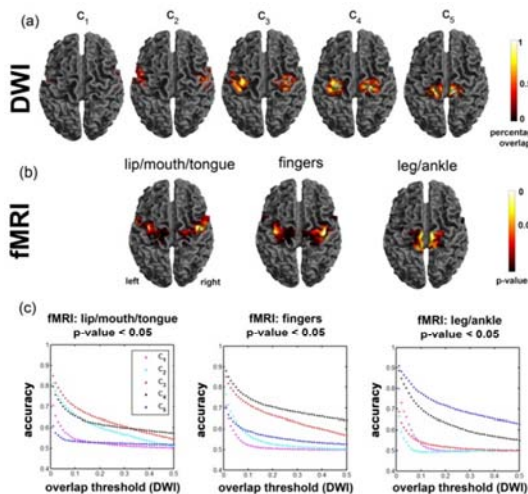


# Localization of Function-specific Segments of the Primary Motor Pathway in Children with Sturge-Weber Syndrome: A Multimodal Imaging Analysis

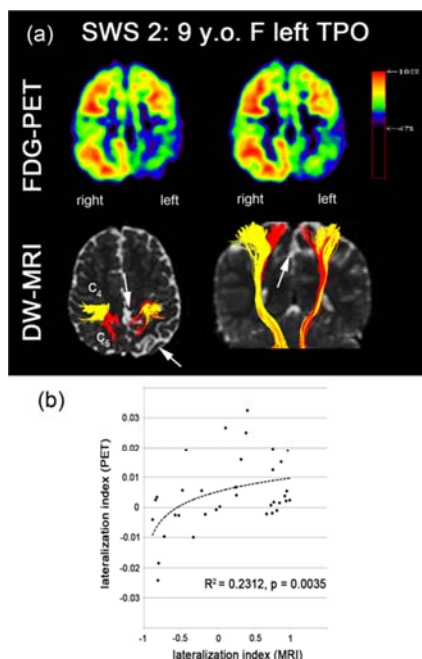
Jeong-Won Jeong<sup>1</sup>, Harry T. Chugani<sup>2</sup>, and Csaba Juhasz<sup>1</sup>

<sup>1</sup>Pediatrics and Neurology, Wayne State University, Detroit, Michigan, United States, <sup>2</sup>Pediatrics, Neurology, and Radiology, Wayne State University, Detroit, Michigan, United States

**Targeted audience:** clinical trainees and researchers in pediatric neuroradiology. **Purpose:** Sturge-Weber syndrome (SWS) is a rare disorder associated with a variety of nervous system problems, including motor deficit, visual field impairment, cognitive decline and seizures<sup>1</sup>. Integrity of corticospinal tract (CST) and related motor functions is a critical issue in SWS children who undergo presurgical evaluation due to intractable seizures. However, the degree of motor cortex and CST involvement is often difficult to determine, especially in children who are unable to cooperate with functional MRI (fMRI). To investigate whether diffusion weighted imaging (DWI) tractography can provide a functional localization of primary motor area segments in-vivo, we developed a new method based on connectivity of CST between precentral gyrus (PCG) and posterior limb of internal capsule (PIC). In the present study, we have analyzed normally developing children where fMRI activation maps of mouth/lip, fingers, and leg/ankle areas were available as gold standards to estimate the accuracy of the proposed methodology. Subsequently, we demonstrated the clinical feasibility and relevance of our approach by performing a multi-modal correlation between 2-deoxy-2-[<sup>18</sup>F] fluoro-D-glucose [FDG] PET abnormalities of the sensorimotor regions and DWI tractography of CST localization in children with unilateral SWS. **Methods:** Thirty-two normally developing right-handed children (ND, age: 10.0±3.3 years, 4.3-17.8 years, 21 boys) and seven children with unilateral SWS and seizures (SWS, age: 3.0±2.8 years, 1.1-9 years, 6 boys) were investigated by 3-Tesla DWI MRI. An independent component analysis based Gaussian mixture model<sup>2</sup> was performed to identify multiple fibers crossing in voxels of whole brain. MNI-space PCG and PIC regions were divided into 10 equi-length segments and transferred into native-space of normal subjects to measure the average pattern of fibers connecting each of the 10 PCG-segments, PCG(i=1,2,...,10) to 10 PIC-segments, PIC(j=1,2,...,10). For each PCG(i), we measured the number of fibers [n(i,j)] connected to each of 10 PIC(j=1,2,...,10), which approximates the probabilistic fiber distribution between PIC(i): seed region and PCG(i): target region. To cluster the segments of PCG(i) showing similar patterns of n(i,j), the present study utilized conventional dendrogram analysis based on the agglomerative hierarchical cluster tree with group average distance. This analysis segments n(i,j) into multiple clusters, c<sub>k</sub> that minimize pair-wise distances of n(i,j) in normal group. The present study assumes that the resulting cluster, c<sub>k</sub>, corresponds to individual CST pathways, involved in unique motor functions. Thus, the PCG segments belonging to cortical terminals of individual fiber cluster, c<sub>k</sub>, are considered to indicate unique motor areas. A fiber visitation map of c<sub>k</sub> was then created by counting the number of fibers intersected per voxel<sup>3</sup>. Finally, the resulting map was normalized to MNI space using the spatial deformation derived from the process of normalization of the b0 image, averaged across all subjects, and scaled by a value of maximum visitation in the map, which defined a percentage overlap map. The percentage overlap map of each c<sub>k</sub> was compared with primary motor areas determined by fMRI. Receiver operating characteristic (ROC) curve analysis was utilized to evaluate the accuracy of DWI segmentwise clusters against the gold-standard fMRI. Also, the resulting PCG-clusters were used to quantify lateral-medial CST projection and hypoglycose metabolism in patients with SWS, that may indicate abnormal motor regions affected by SWS. **Results:** In healthy children, five PCG-clusters, c<sub>k=1,2,3,4,5</sub> were found to have unique CST courses, corresponding to CST segments of mouth/lip, fingers, and leg/ankle primary motor areas determined by fMRI (Fig. 1). The ROC plots show the accuracy measure of individual c<sub>k</sub> to detect fMRI activations responding to "mouth/lip", "finger", and "leg/ankle" movements at p-value= 0.05, suggesting that the DWI segmentwise clusters achieve the highest accuracies of 0.84 (mouth/lip), 0.88 (fingers), and 0.91 (leg) at the overlap threshold of 0.05. In children with SWS, reduced fibers in these PCG clusters were highly correlated with glucose-hypometabolism on PET (Fig. 2; R<sup>2</sup>=0.23, p-value=0.0032). **Discussion and Conclusion:** The presented method can detect impaired CST segments corresponding to specific motor functions in young children, who cannot cooperate for fMRI. This approach can be clinically useful for a non-invasive presurgical evaluation of cortical motor areas in such children.



**Figure 1.** Comparison of DWI segmentwise clustering localization and fMRI group analysis obtained from 12 normal subjects (test samples). (a) Percentage overlap maps of five pathways, c<sub>k=1,2,...,5</sub>. (b) Lip/mouth/tongue, fingers, and leg/ankle areas determined by fMRI. (c). Accuracy measures between DWI and fMRI obtained from the ROC analysis.



**References:** 1. Bodensterner JB, Roach ES. Sturge-Weber syndrome, The Sturge-Weber Foundation, New York: Mt. Freedom; 2010. 2. Jeong JW, Asono E, Yeh FC, et al. Independent component analysis tractography combined with a ball-stick model to isolate intra-voxel crossing fibers of the corticospinal tracts in clinical diffusion MRI. Magn Reson Med. 2012;doi:10.1002/mrm.24487. 3. Ciccarelli O, Tossy AT, Parker GJ, et al. Diffusion tractography based group mapping of major white-matter pathways in the human brain. Neuroimage. 2003;19:1545-55.

**Figure 2.** (a) FDG hypometabolism and reduced fiber density assessed in a 9 years old girl with SWS affecting the left temporal, parietal, and occipital lobes. Significantly reduced glucose uptake and CST projection were found near c<sub>4</sub> and c<sub>5</sub> in left hemisphere, marked by white arrows pointing out atrophic cortex and white matter infarct. (b) PET-MRI correlation coefficient, R. Lateralization index of PET (FDG uptake) and MRI (fiber count) was evaluated per c<sub>k</sub> in 7 SWS patients.