

Magnetisation Transfer contrast to enhance detection of neuromelanin loss at 3T in Parkinson's disease.

Stefan Theodor Schwarz¹, Nin Bajaj², Paul S Morgan³, Scott Reid⁴, Penny Gowland⁵, and Dorothee P Auer¹

¹Division of Radiological and Imaging Sciences, University of Nottingham, Nottingham, Nottinghamshire, United Kingdom, ²Department of Neurology, Nottingham University Hospitals NHS Trust, Nottingham, Nottinghamshire, United Kingdom, ³Medical Physics, Nottingham University Hospitals NHS Trust, Nottingham, Nottinghamshire, United Kingdom, ⁴Clinical Science Development Group, GE Healthcare, Diagnostic Imaging, Hatfield, Hertfordshire, United Kingdom, ⁵School of Physics & Astronomy, University of Nottingham, Nottingham, Nottinghamshire, United Kingdom

Background/Purpose: Parkinson's disease (PD) is characterised by a loss of dopaminergic neurons of the substantia nigra (SN) which results in dopamine deficiency throughout cortical and sub-cortical grey matter as main cause of PD symptoms. Dopaminergic cell loss can be indirectly demonstrated by usage of radio labelled tracers of dopaminergic transporter proteins in the basal ganglia. To date, there is no direct biomarker available to index SN neurodegeneration. Dopaminergic cell loss in PD causes depletion of pigmented, neuromelanin containing neurons of the SN. Neuromelanin in its chemical and physical properties resembles melanin with its strong paramagnetic properties. There is increasing evidence to suggest that T1 weighted MRI at 3T can be used to demonstrate the pigmented neurons of the SN as well as the loss of pigmentation in PD(1; 2). The neuromelanin contrast appears to be related to magnetisation transfer (MT) predicting that additional MT pulses would enhance the contrast. **The purpose of this study** was to assess whether MT enhanced neuromelanin MRI at 3T would reliably demonstrate the dopaminergic cell loss in patients with PD. Diagnostic efficacy of 'on' vs. 'off' resonance MT schemes were compared with that of published standard neuromelanin MRI. To further validate MT - MRI as potential biomarker, nigral signal loss in patients with PD was correlated with the Unified-PD-Rating Scale (UPDRS) as a measure of disease severity. Lastly, robustness of protocols between different scanner platforms was assessed. **Methods:** 19 subjects (9 controls and 10 age and gender matched PD, disease duration 0.3–7 years, UPDRS 6–43) were scanned at 3T (Philips Achieva MR scanner) with an optimised T1 weighted fast spin echo sequence (T1w FSE, TR, 904 ms; TE, 9 ms; slice thickness, 2.5 mm; 0.47 x 0.47 pixel resolution; 4 averages, 12 slices; acquisition time: 12 minutes) with additional standard 'off resonance' MT pulse. In 14 (7 controls and 7 PD) the scan was repeated with an 'on resonance' MT pulse. 4 out of 19 participants (2 controls and 2 PD) were additionally imaged at 3T (MR750, GE Healthcare) with a spin echo MT sequence (TR, 600 ms, TE, 10 ms; slice thickness, 2.5 mm; 0.375 x 0.375 pixel resolution; 4 averages, 12 slices, acquisition time 14 min, MT, 1200 Hz off centre frequency). Neuromelanin related nigral signal volume was calculated using an individually determined signal intensity (SI) threshold equivalent to mean background signal + 3SD (over background region) on 3 consecutive brain stem slices containing the SN as previously published(2). Effect sizes (ES) were calculated using SPSS V19.0/ANOVA as η^2 . According to Cohen(3) ES are considered small if $\eta^2 \leq 0.01$, moderate if = 0.059 and large if ≥ 0.138 . Linear regression analysis (SPSS V19.0) was used for correlation statistics. **Results:** As demonstrated in the previous study using a SPIR fat-saturation pulse to convey a MT effect(2) throughout all T1w scans with additional 'on-' or 'off' resonance MT pulse the SN and locus coeruleus were clearly visible as high signal intensity region in the anatomically expected location. There was no significant differences in thresholded high signal SN volumes when comparing 'on-' and 'off' resonance MT pulses in the same population (n=14, 7 PD and 7 controls, mean \pm SD; 56.1 \pm 32.2 mm³ [MT 'off resonance']; 59.4 \pm 33.9 mm³ [MT on resonance], p=0.35) or when looking at the PD or controls separately. Similar volumes were also seen for 'off resonance' MT between platforms (n=4, Figure 1). The neuromelanin rich SN volume was significantly smaller yielding a large ES in people with PD for all protocols (**MT 'off resonance'** mean difference [mean diff.] =42.1 mm³, p<0.001, $\eta^2=0.52$, n=19; **MT 'on resonance'** mean diff.=50.8 mm³, p<0.001, $\eta^2=0.6$, n=14 and **GE scanner MT 'off resonance'** mean diff.=51.5 mm³, p=0.09, $\eta^2=0.83$, n=4). All protocols allowed classification with high diagnostic accuracy, 1/19, 1/14 and 0/4 misclassified respectively. This compares favourably with the indirect SPIR based MT protocol previously published with 4/22 misclassified cases and smaller disease effect size [mean diff.=34.3 mm³, p=0.003, $\eta^2=0.36$, n=22, previously published(2)]. Importantly, we found a significant correlation of neuromelanin related signal loss and PD severity assessed by UPDRS for both 'off resonance' (see Figure 2) and 'on resonance' MT protocols (**MT 'off-res'**, n=10, adjusted $r^2=0.44$, p < 0.05; **MT 'on-res'**, n=7, adjusted $r^2=0.52$, p<0.05). **Summary/Discussion:** This study demonstrates an improved disease effect size and diagnostic accuracy of adding MT 'on' or 'off' resonance pulse to the T1 weighted neuromelanin sensitive MRI scan at 3T. The diagnostic accuracy was unaffected by the choice of MT pulse ('on-' or 'off' resonance) and the platform used. This study confirms and expands on previous reports on the potential of NM signal to become a useful clinical marker of disease progression in PD. Addition of volumetric analysis and an improved platform independent protocol allowed us to yield a strong disease effect size and a moderately strong correlation with clinical severity. This underscores the potential of MT-T1 weighted MRI at 3T to track disease progression in PD. **Conclusion:** T1w spin echo MRI with additional MT pulse at 3T improves the observable neuromelanin related signal loss in PD. The proposed hyperintensity based volumetric analysis provides a biomarker with high diagnostic accuracy, correlated with disease severity and hence progression, applicable across scanner platforms. **References:** 1. Sasaki et al, *Neuroreport*. 2006;17(11):1215–8., 2. Schwarz et al., *Mov. Disord.* 2011;26(9):1633–1638., 3. Cohen J. *Statistical Power Analysis for the Behavioral Sciences*. 2nd ed. Routledge Academic; 1988.

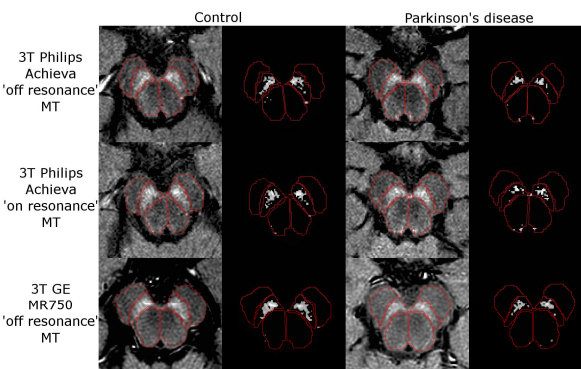


Figure 1: Different protocols for MT spin echo T1 scans and thresholded neuromelanin maps in representative control and person with PD. First and third column – raw image, second and fourth column, suprathreshold pixels. First and third rows 'off resonance' MT pulse, second 'on resonance'.

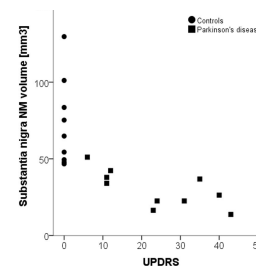


Figure 2: Neuromelanin related SN signal volume assessed by T1w FSE MRI with additional 'off resonance' MT pulse. Note the almost complete separation of controls and PD and the correlation of UPDRS with the SN - MN signal volume (one PD miss-classified).