

C7 NERVE ROOT SENSORY MAPPING: A 9.4T BOLD FUNCTIONAL MRI INVESTIGATION

Jacques Machol IV¹, Rupeng Li², Patrick Hettinger¹, Nicholas Flugstad¹, Ji-Geng Yan¹, Hani Matloub¹, and James Hyde²

¹Plastic Surgery, Medical College of Wisconsin, Milwaukee, WI, United States, ²Biophysics, Medical College of Wisconsin, Milwaukee, WI, United States

Target Audience: Peripheral nerve surgeons (neurologic, orthopaedic, micro, and plastic surgeons), radiologists, and biophysicists.

Purpose: In the case of severe brachial plexus avulsion injury, the C7 nerve root is identified as a possible donor for nerve transfer (1). This study aims to elucidate the linear sensory makeup of each major upper limb nerve (ulnar, median, radial, and musculocutaneous) by the C7 root cortical map through sensory stimulation. We hypothesize that if the linear makeup is less than the 20% of each nerve, then this will help to expound why C7 is a suitable donor for brachial plexus injury treatment (2).

Methods: An operating microscope (5-10x magnification) was utilized to isolate the brachial plexus and the C7 nerve root in male Sprague-Dawley rats (200 g). A 125 μm diameter stainless steel bipolar electrode was placed around the right C7 nerve root. 9.4T blood oxygen level dependent functional magnetic resonance imaging (BOLD fMRI) was performed while mild electrical C7 root stimulation (10 Hz) was applied. Voxel overlap within the S1FL cortex was compared between the C7 nerve root and peripheral sensation in each major upper limb nerve (3). This was designated the C7 sensory composition percentage of each nerve.

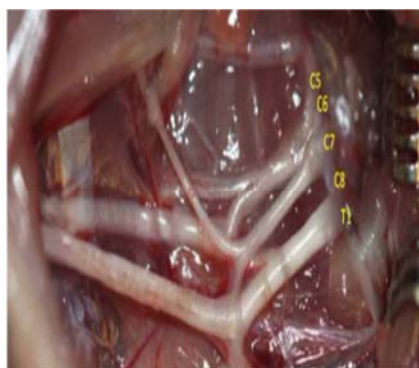


Fig 1. Rat brachial plexus (5.5x).




Fig 2. 9.4T BOLD fMRI Rat Cortex - Sensory Stimulation: A) S1FL C7 B) Radial n. C) Median n. D) Ulnar n. E) Musculocutaneous n. F) Brain Atlas

Results: The C7 nerve root comprises sensation in less than 1% in the musculocutaneous nerve, 6% in the ulnar nerve, 16% in the radial nerve, and 19% in the median nerve ($P < 0.005$ for each).

Discussion: The C7 nerve root sensory cortical representation area only occupies a very small amount of total activated area in all nerve maps. As hypothesized, the overlap is always under 20% for each upper extremity major nerve.

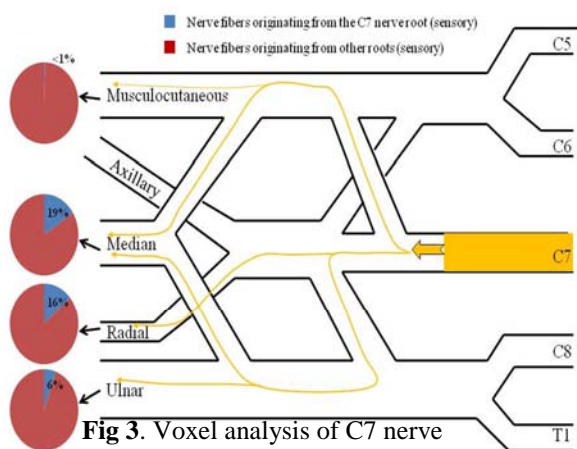


Fig 3. Voxel analysis of C7 nerve sensory root contribution in upper extremity nerve cortical representations in the rat S1FL

Conclusion: These findings are exclusively within the ability of each major nerve to compensate and are likely a facet of why C7 is a suitable donor for brachial plexus injury repair.

References:

1. Gu et al. Seventh cervical nerve root transfer from the contralateral healthy side for treatment of brachial plexus root avulsion. *J Hand Surg Br.* 1992 Oct;17(5):518-21.
2. Lutz et al. Nerve transfer to the median nerve using parts of the ulnar and radial nerves in the rabbit--effects on motor recovery of the median nerve and donor nerve morbidity. *J Hand Surg Br.* 2000;25(4):329-335.
3. Cho et al. Refining the sensory and motor ratunculus of the rat upper extremity using fMRI and direct nerve stimulation. *Magn Reson Med.* 2007 Nov;58(5):901-9.

Funded by grant 2R01EB000215-23A1 NIH United States